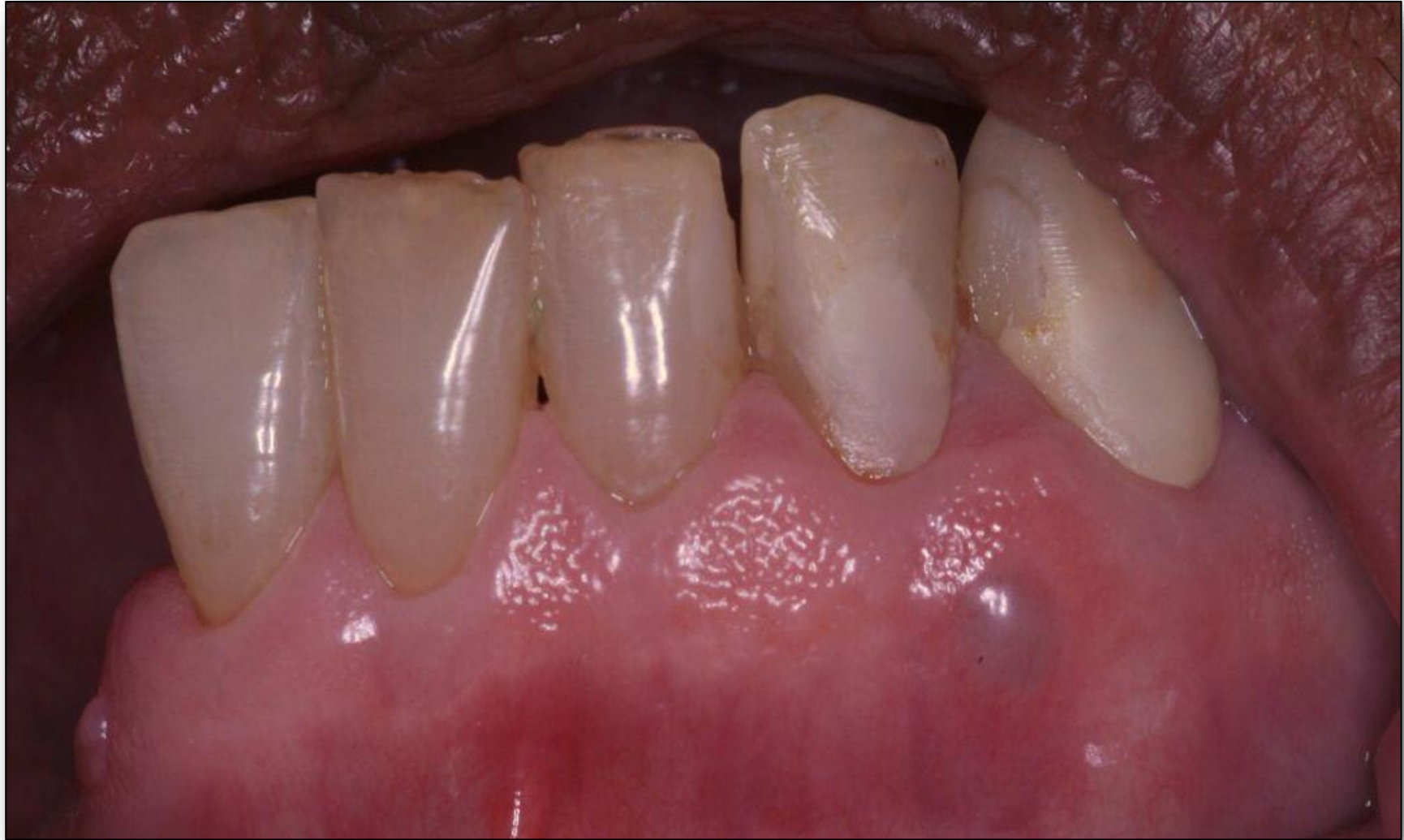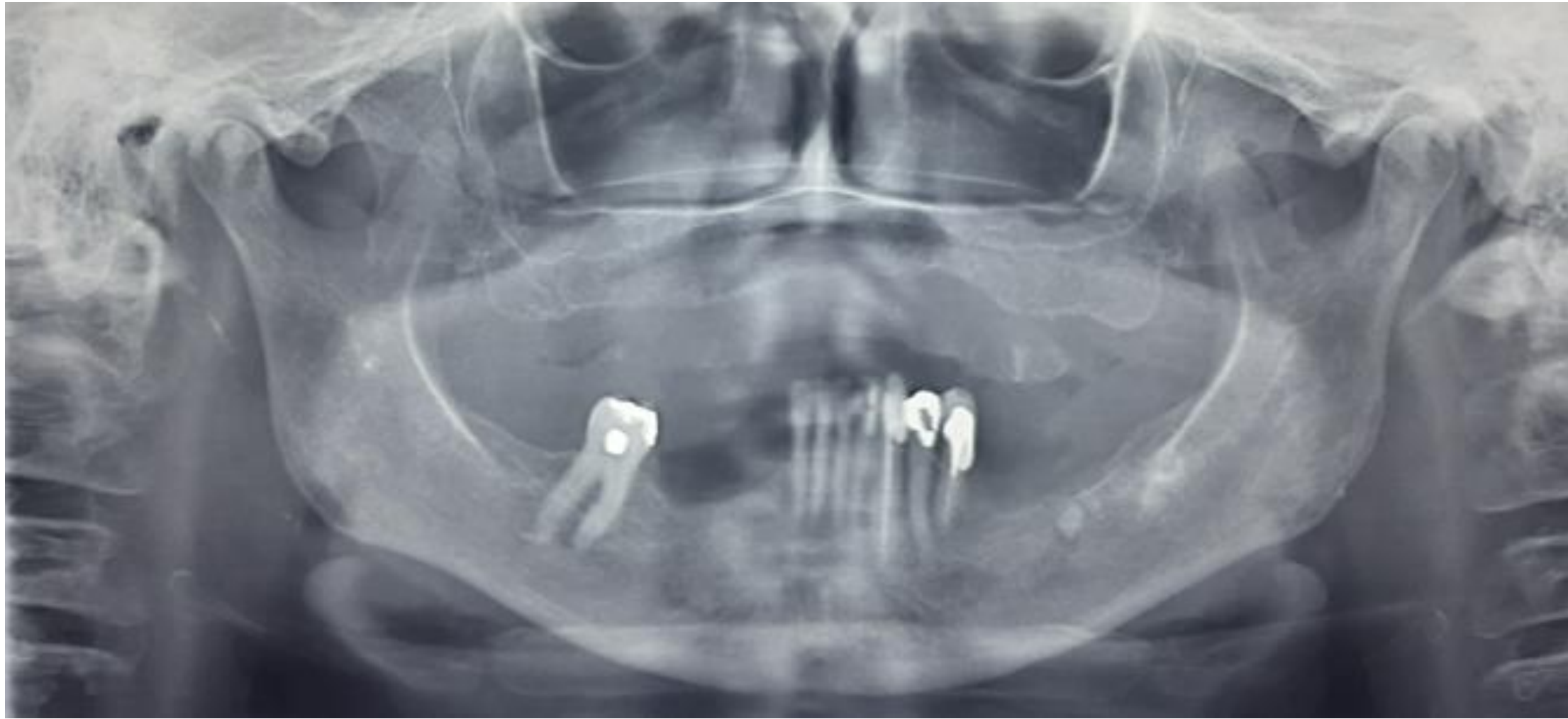
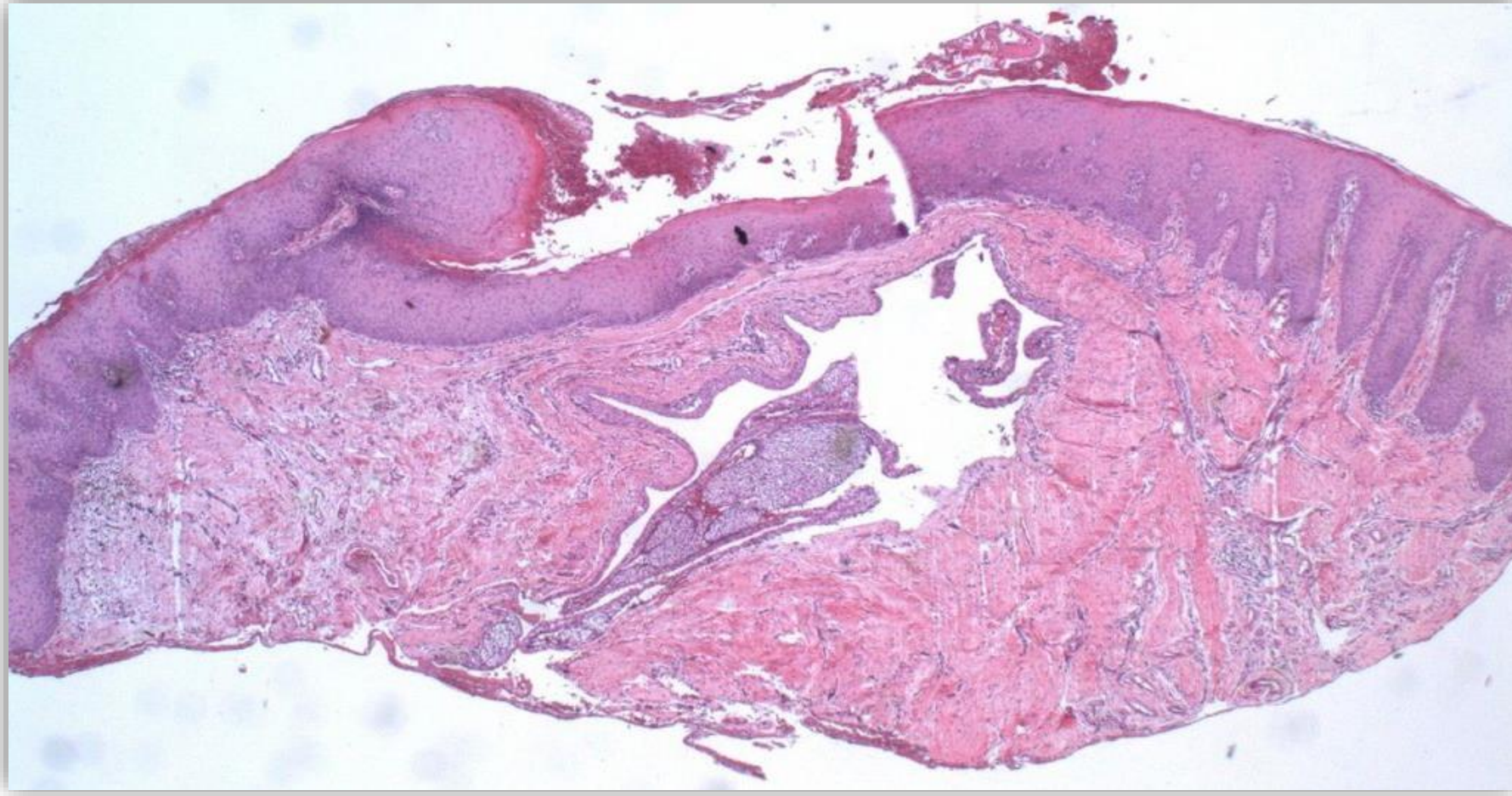
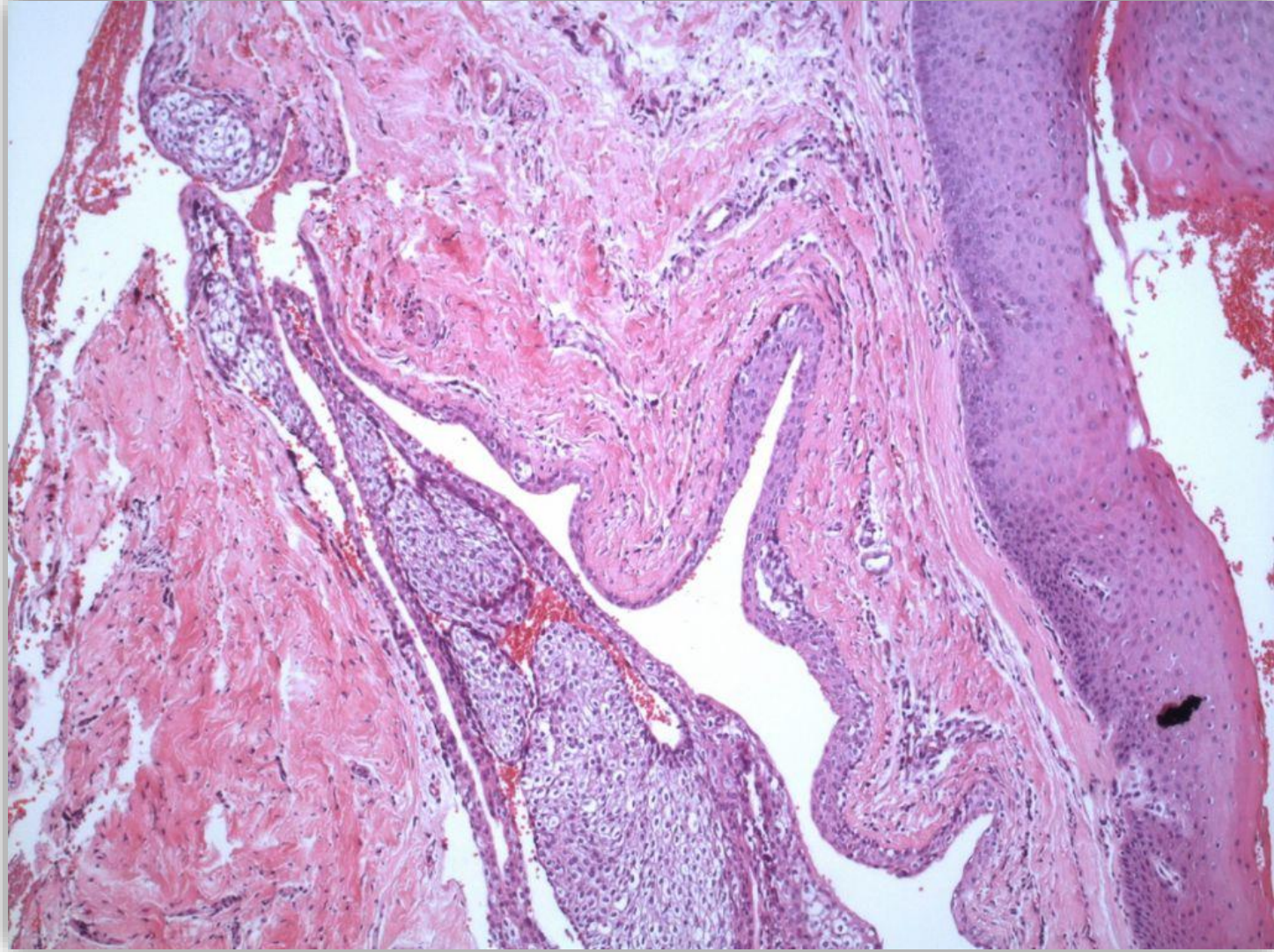


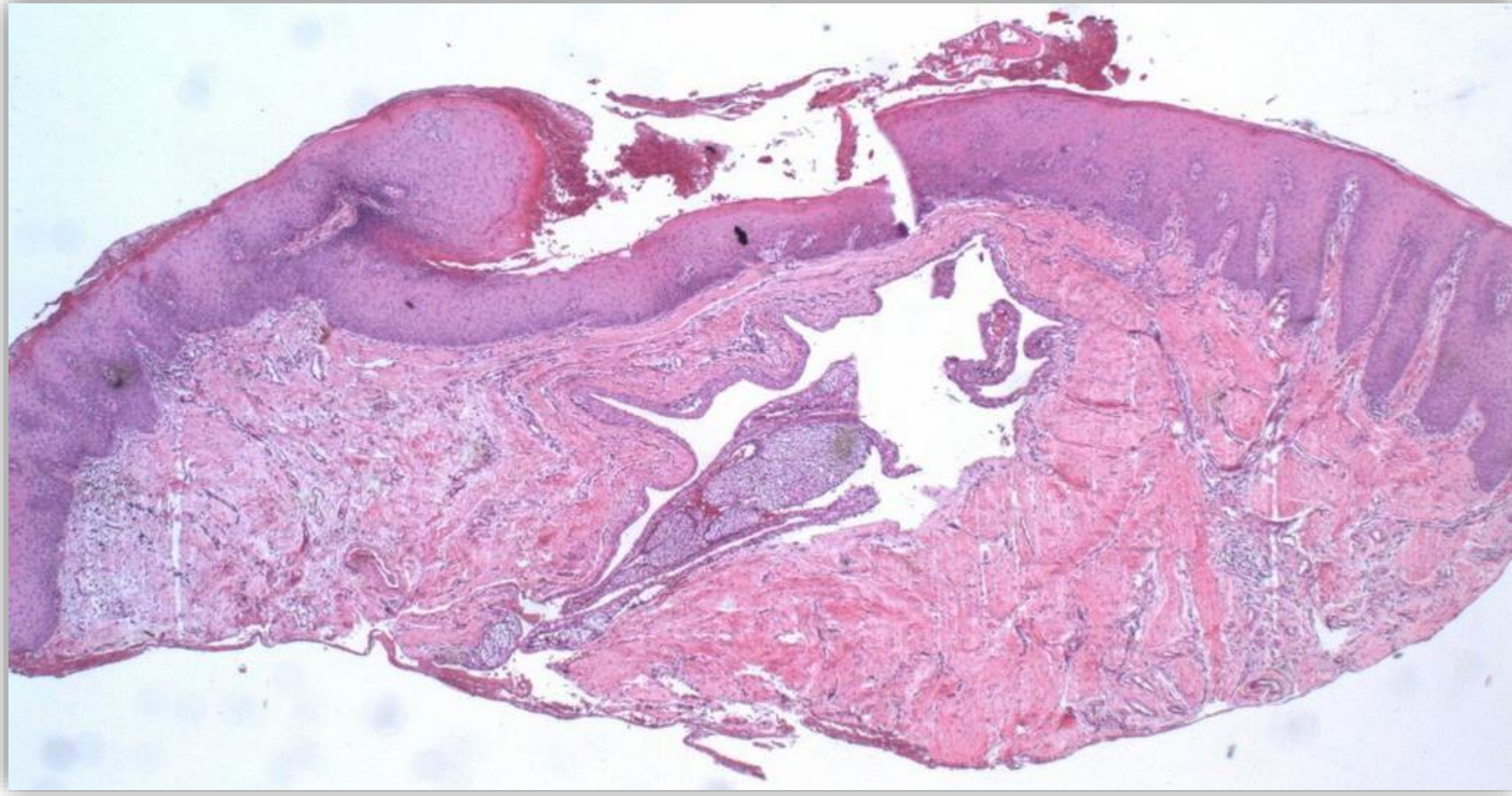
Caso 1
Mulher, 75 anos de idade

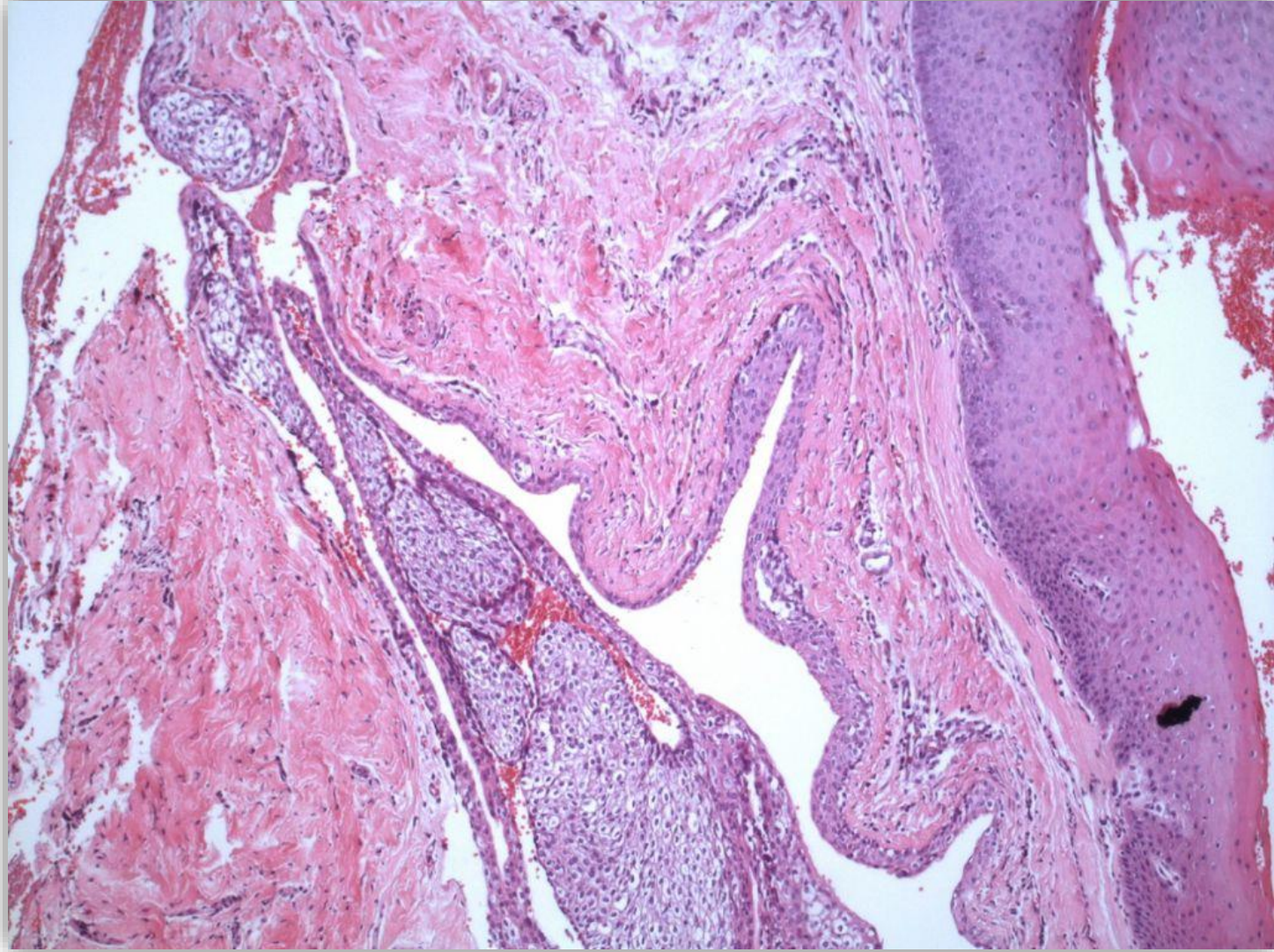


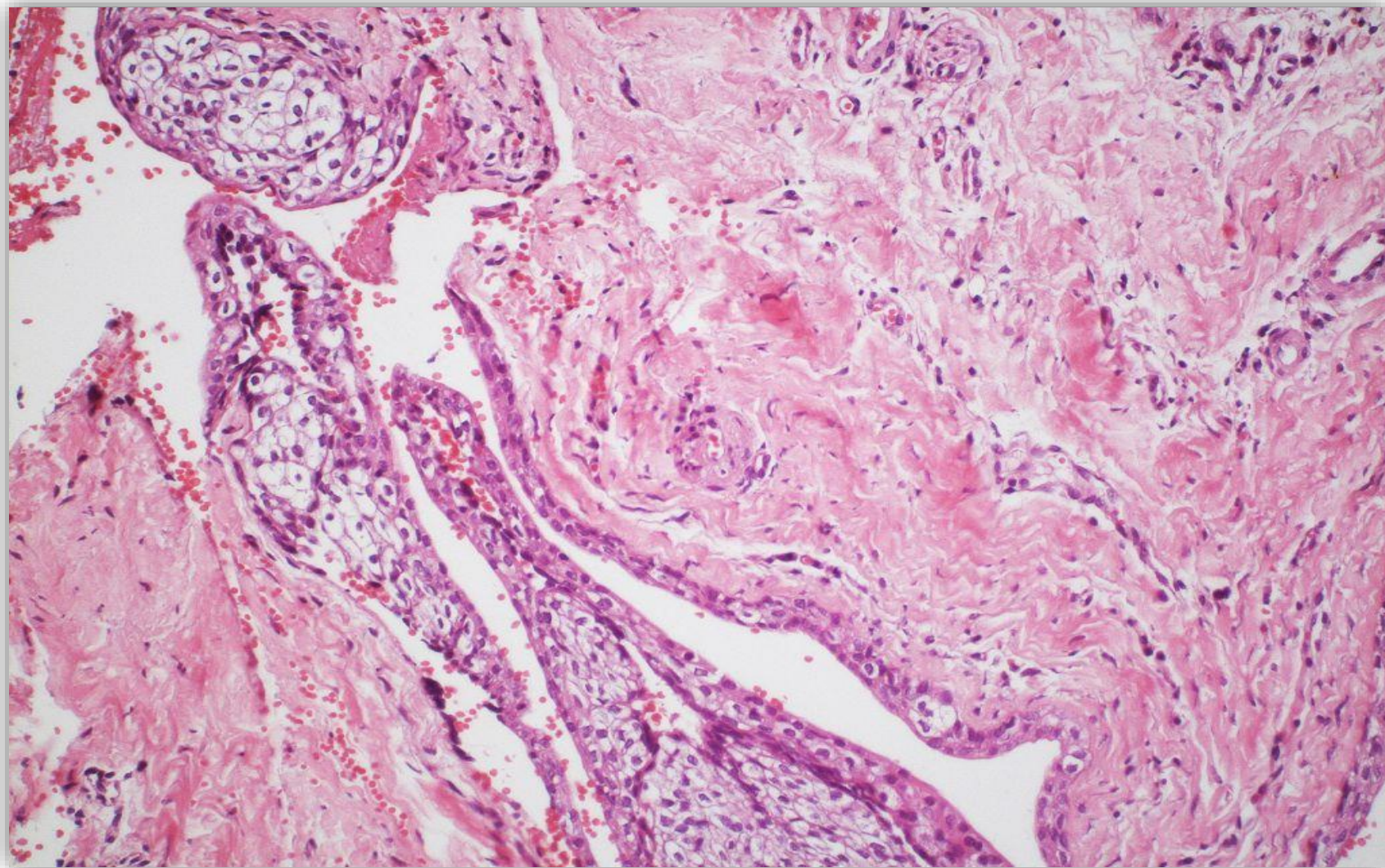






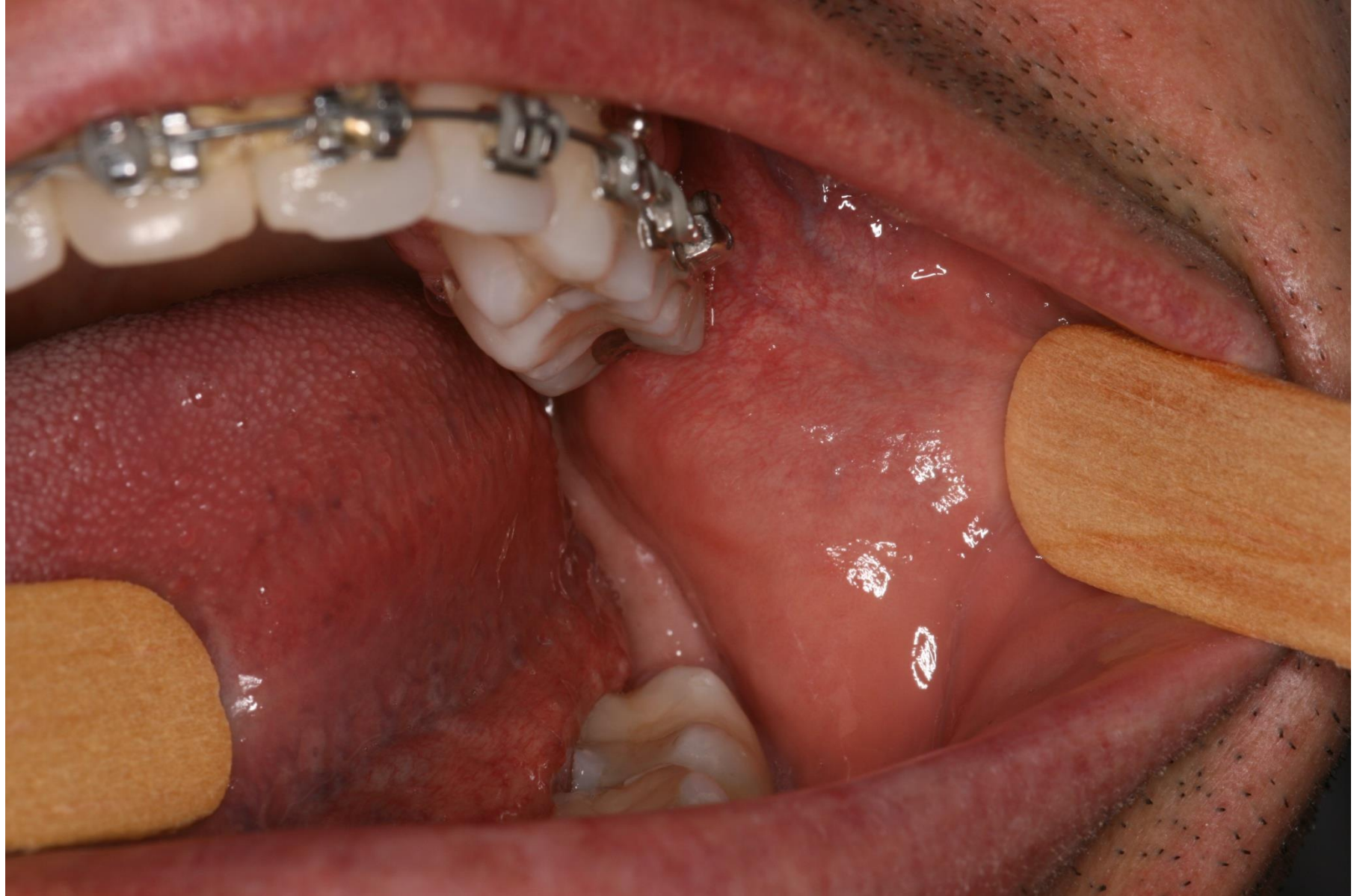




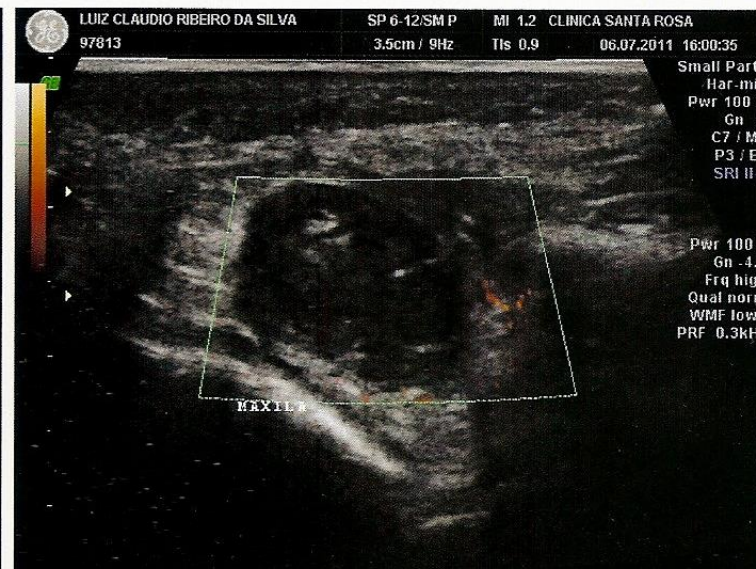
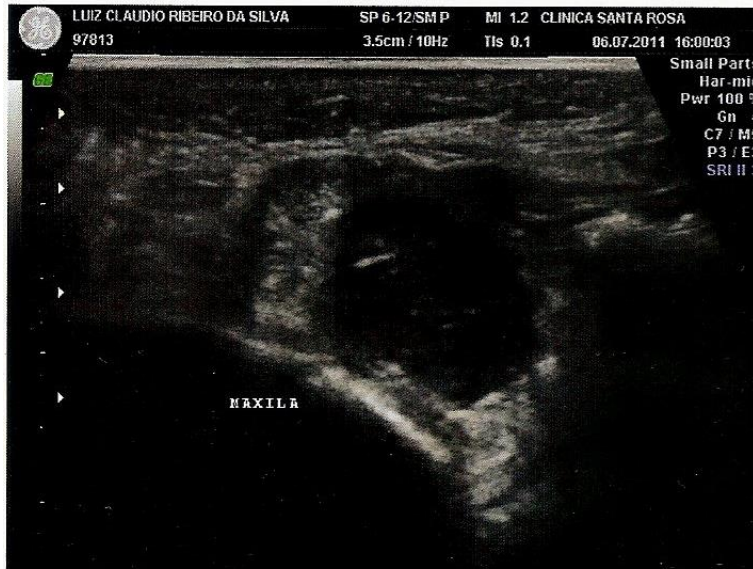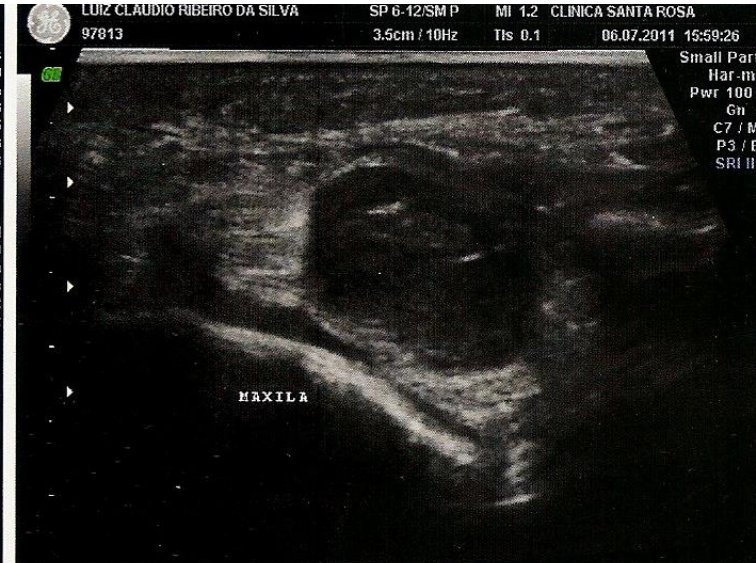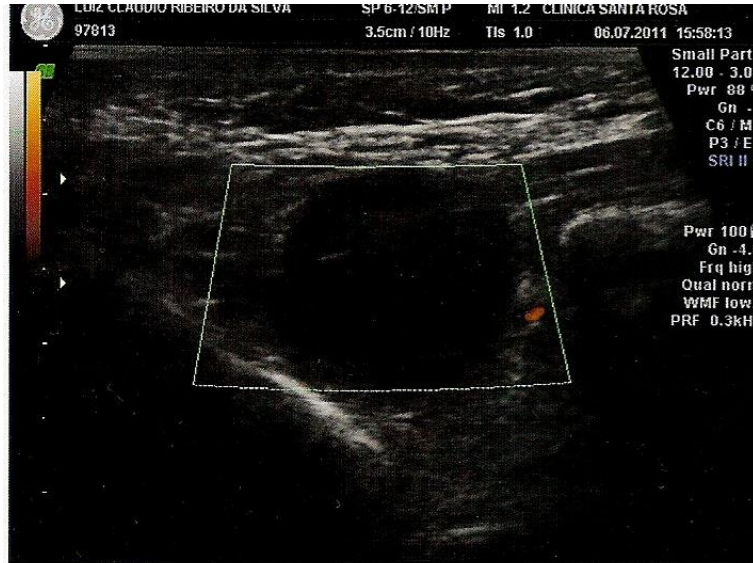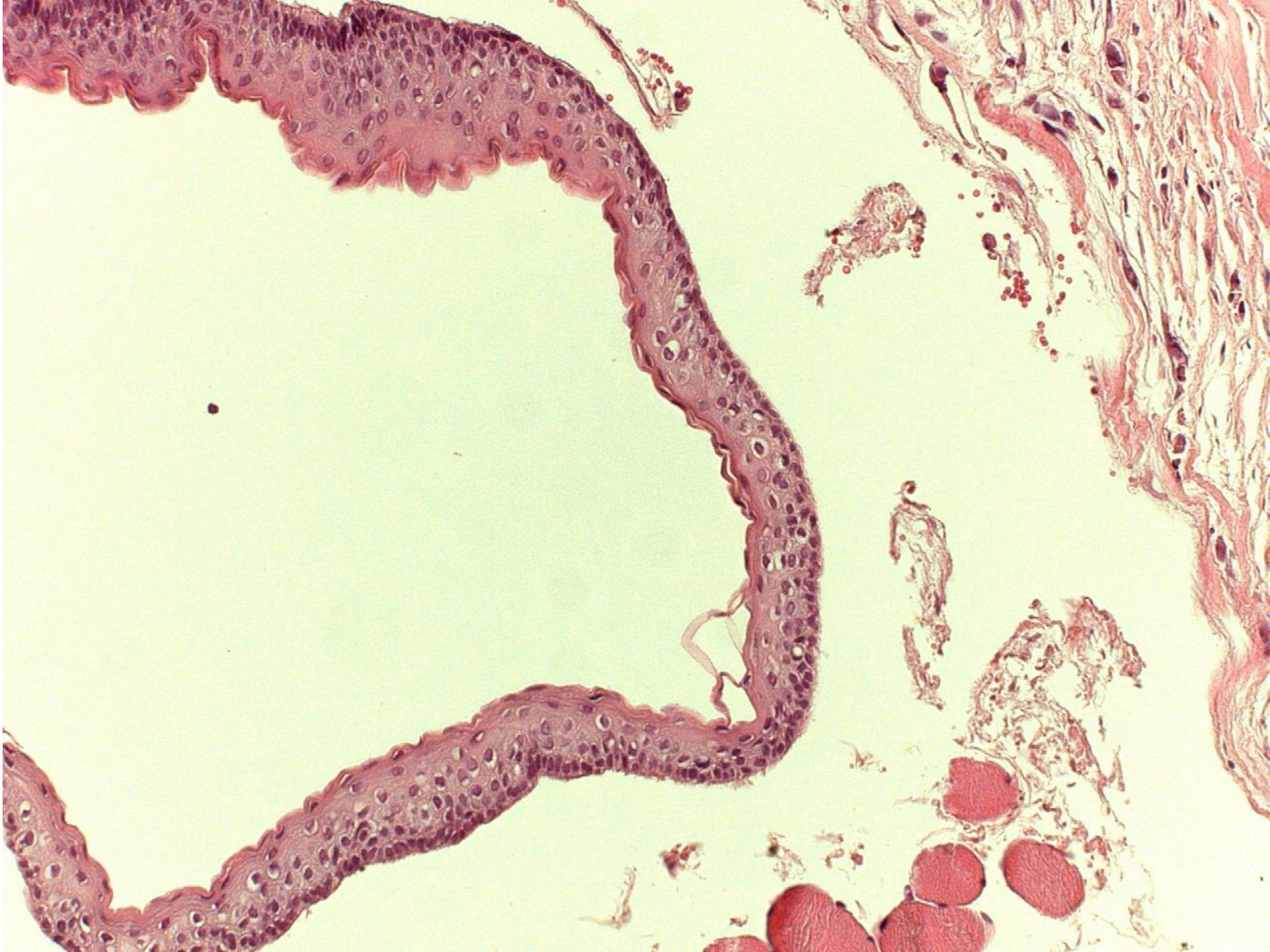
Caso 2

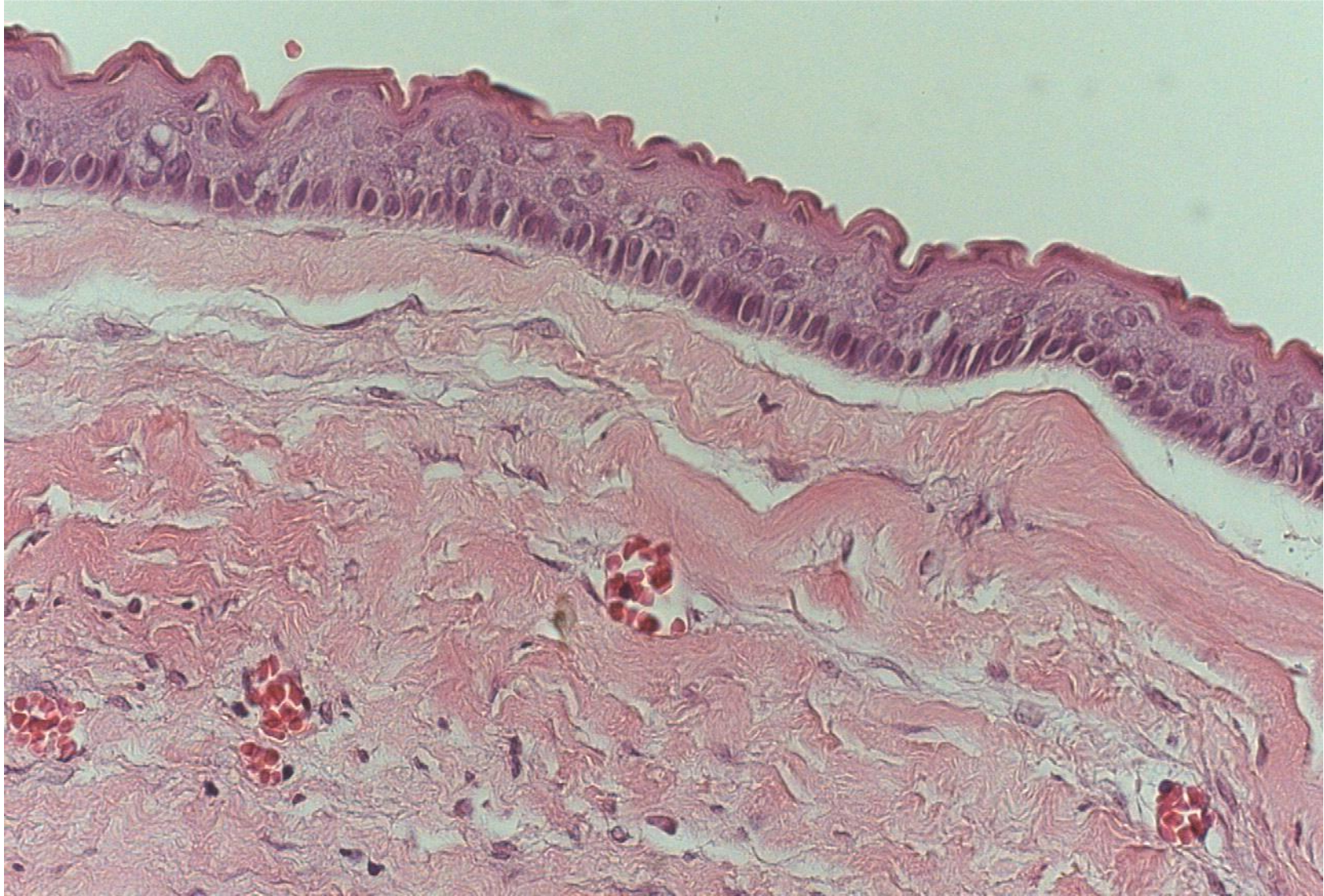
Homem, 37 anos de idade. Queixa principal: “aumento de volume na bochecha”.

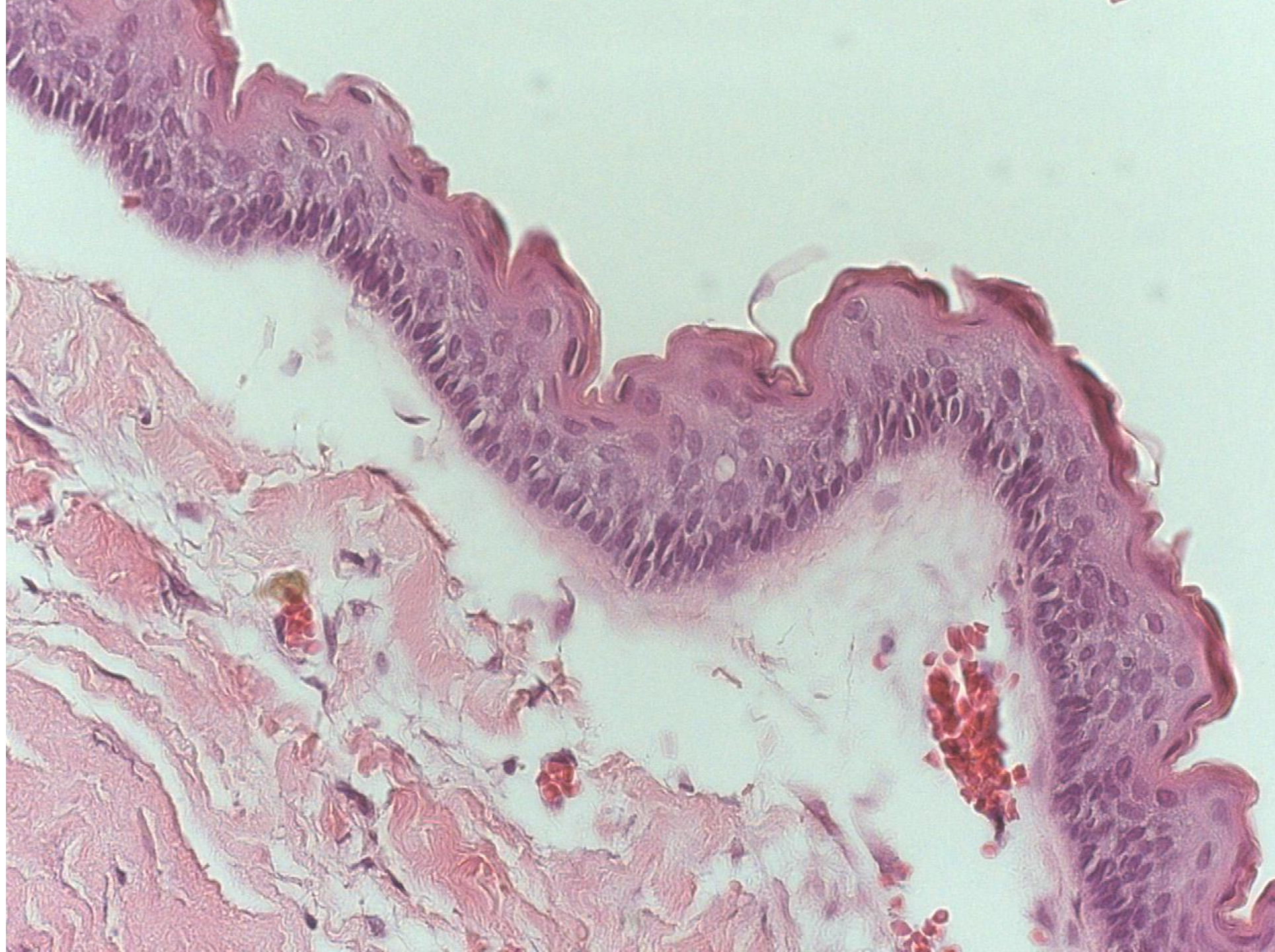


Exames complementares



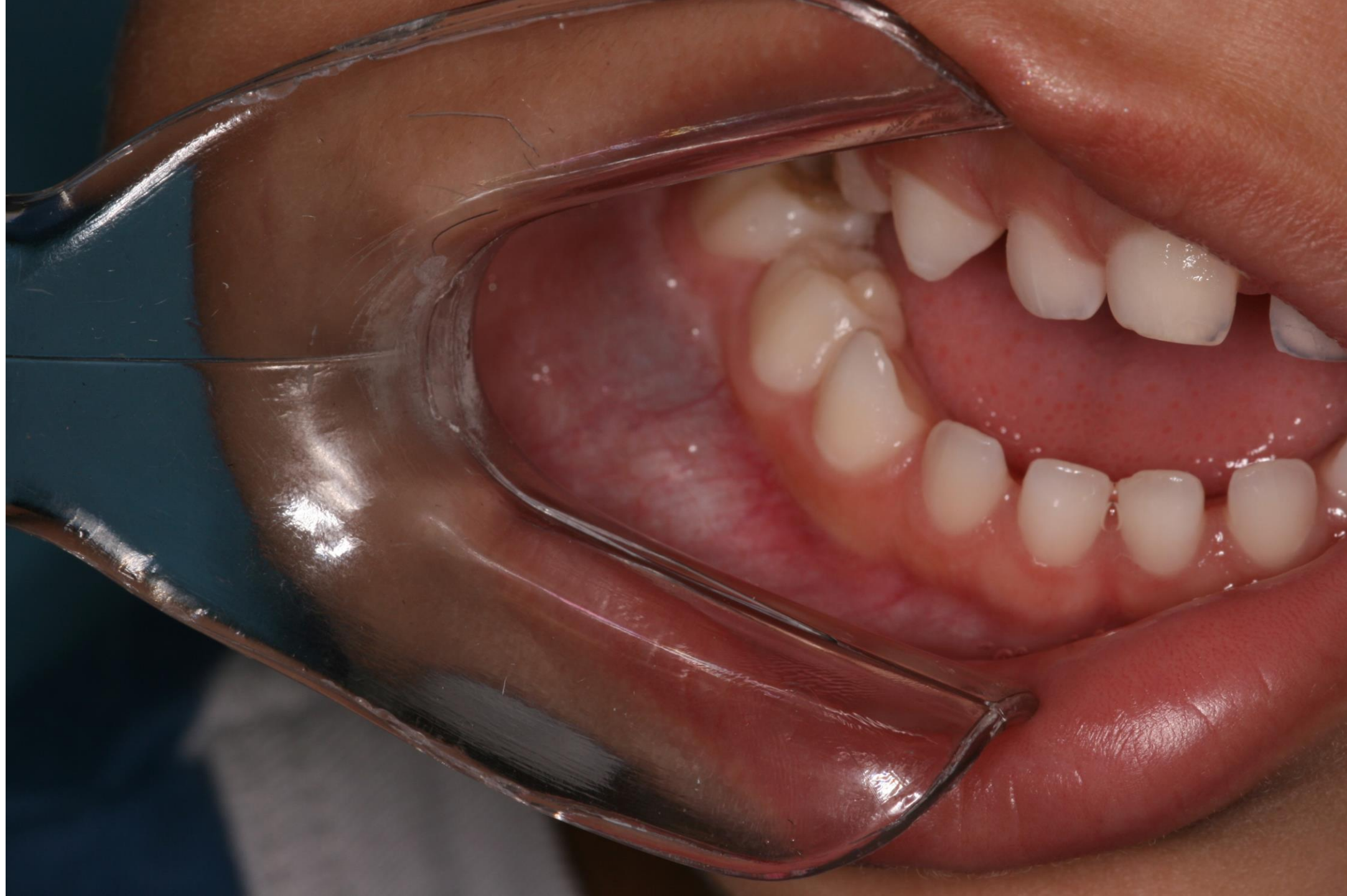


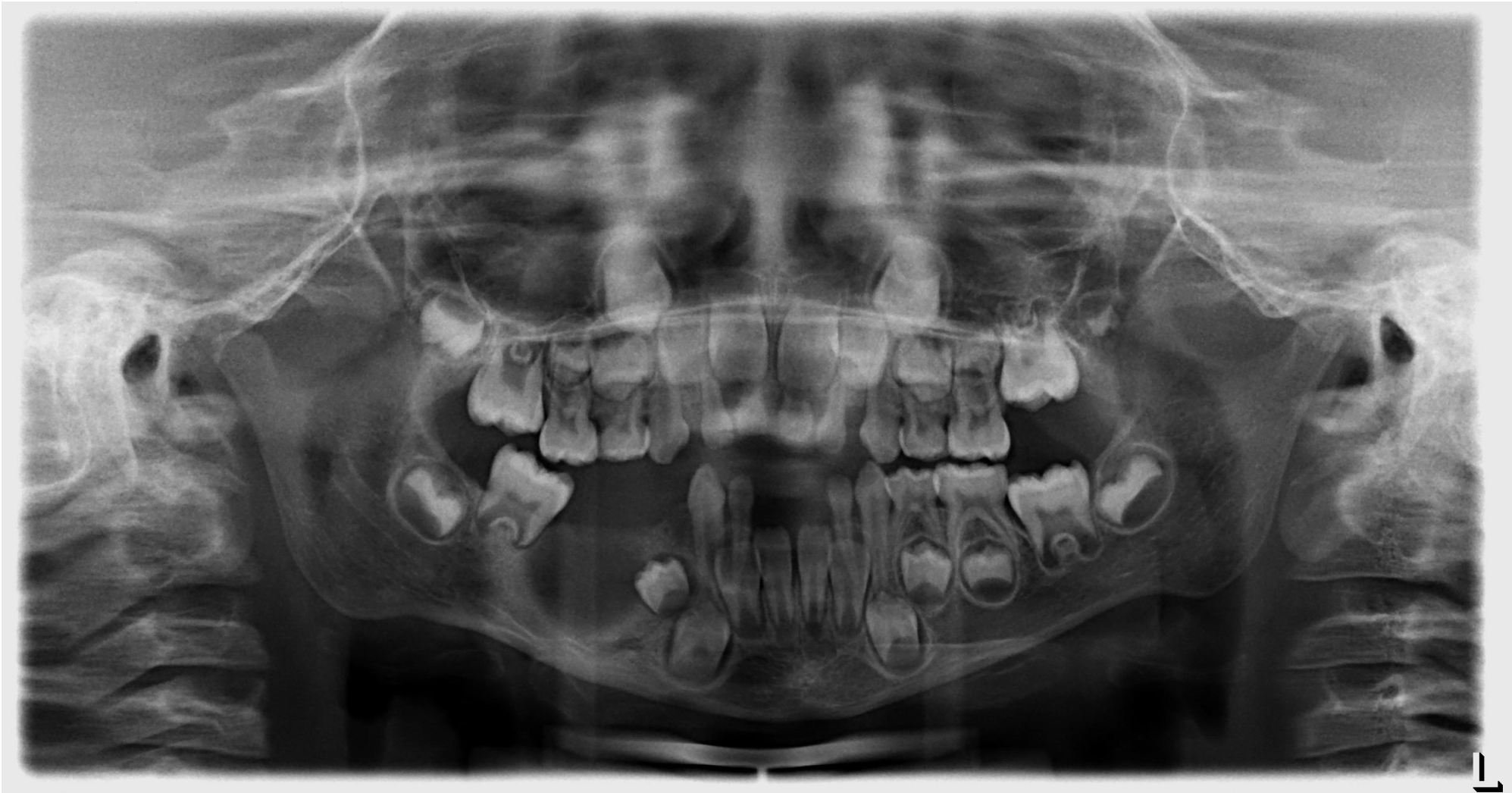


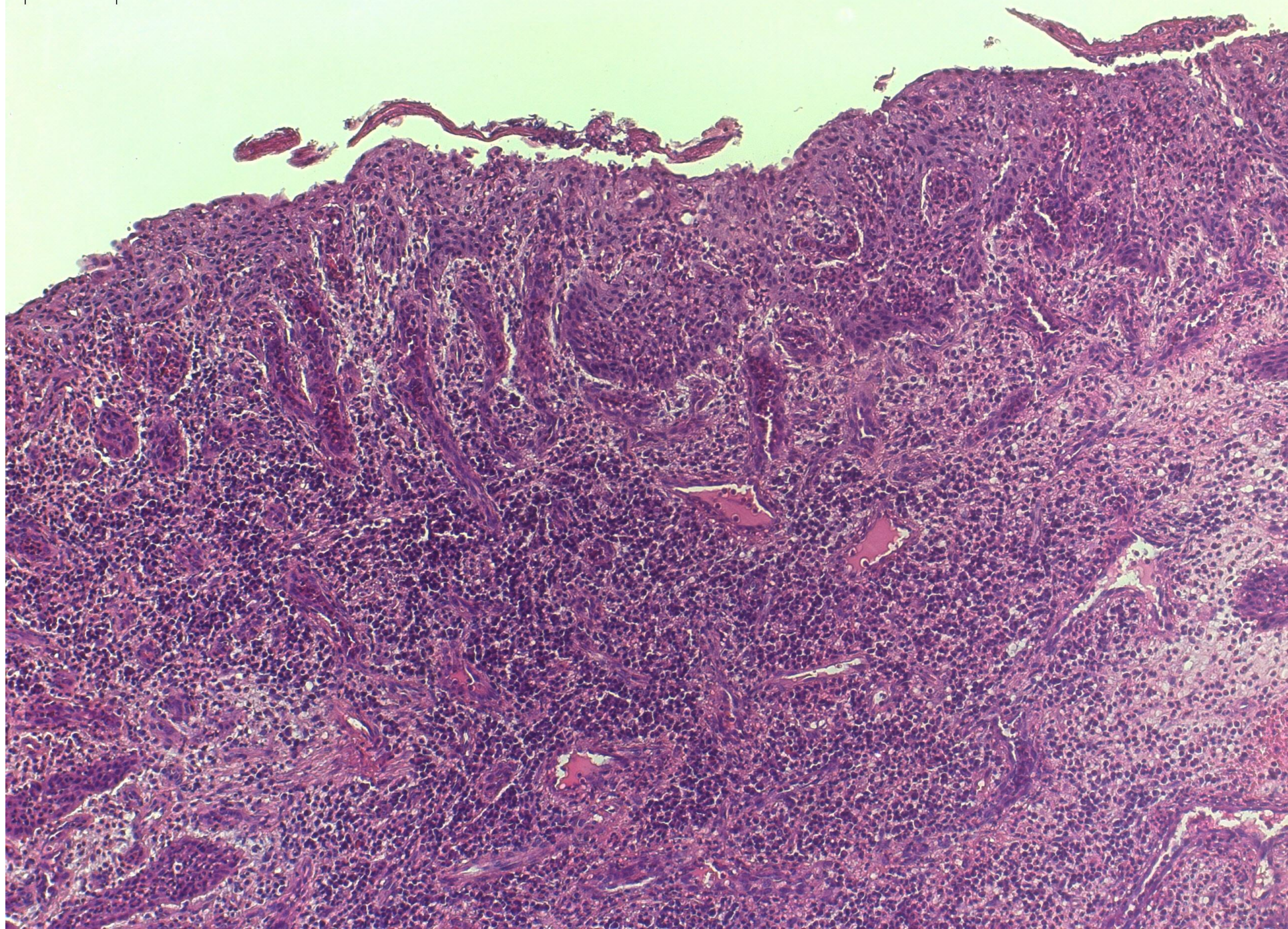
Caso 3

Homem, 4 anos de idade. Queixa principal: “aumento de volume no rosto”.





100 μ m



20 μ m

