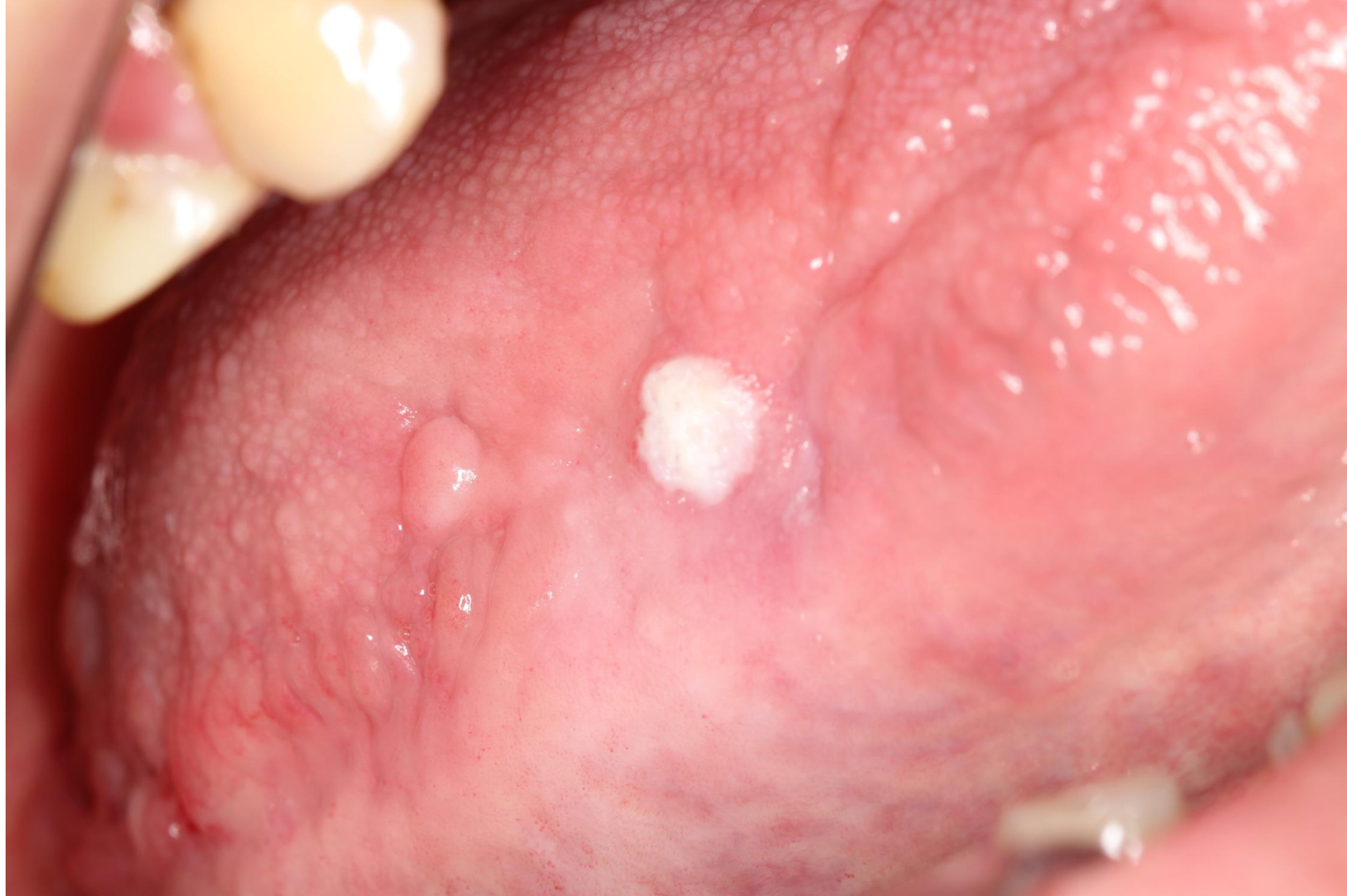

# CASO 1

Paciente masculino, 49 anos. Fumou um maço de cigarro por dia durante 15 anos. Bebe meio fardo de cerveja.

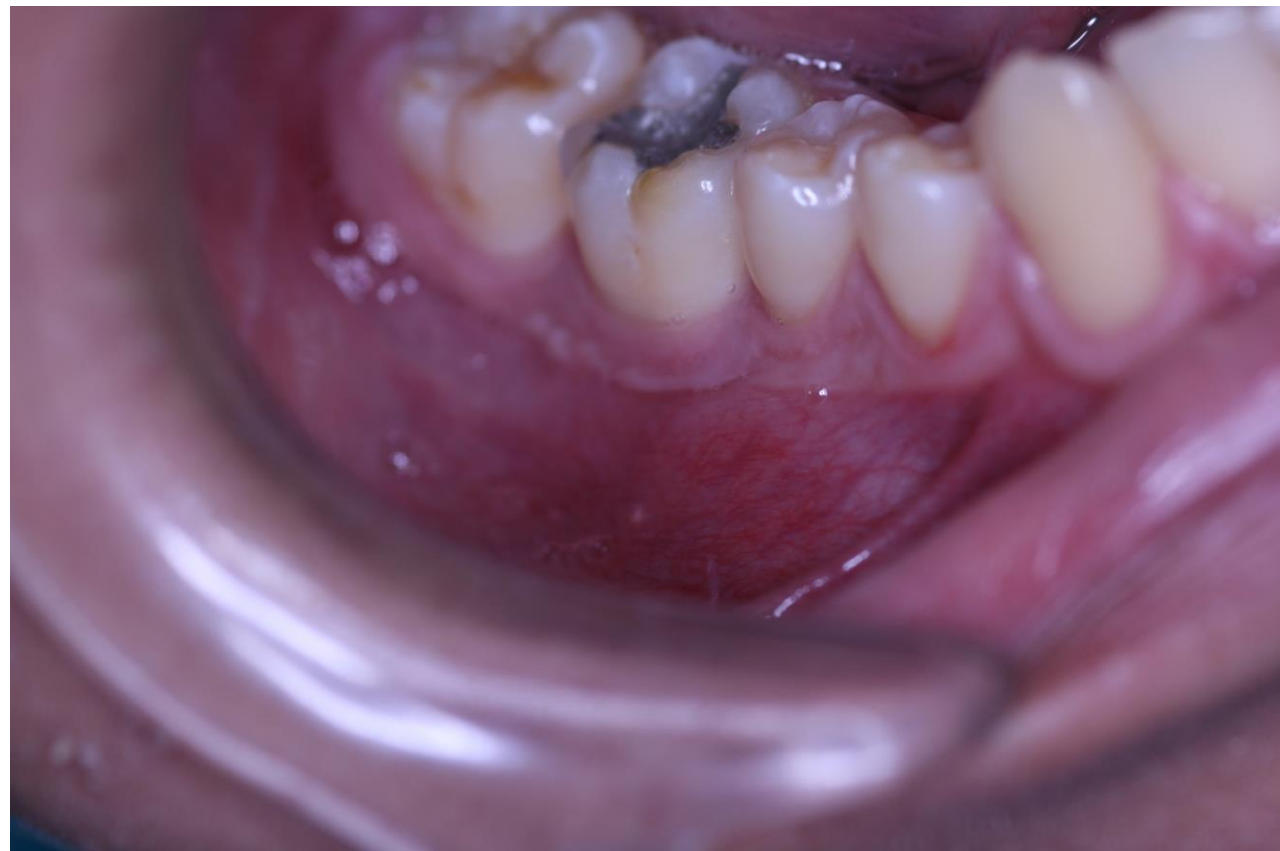
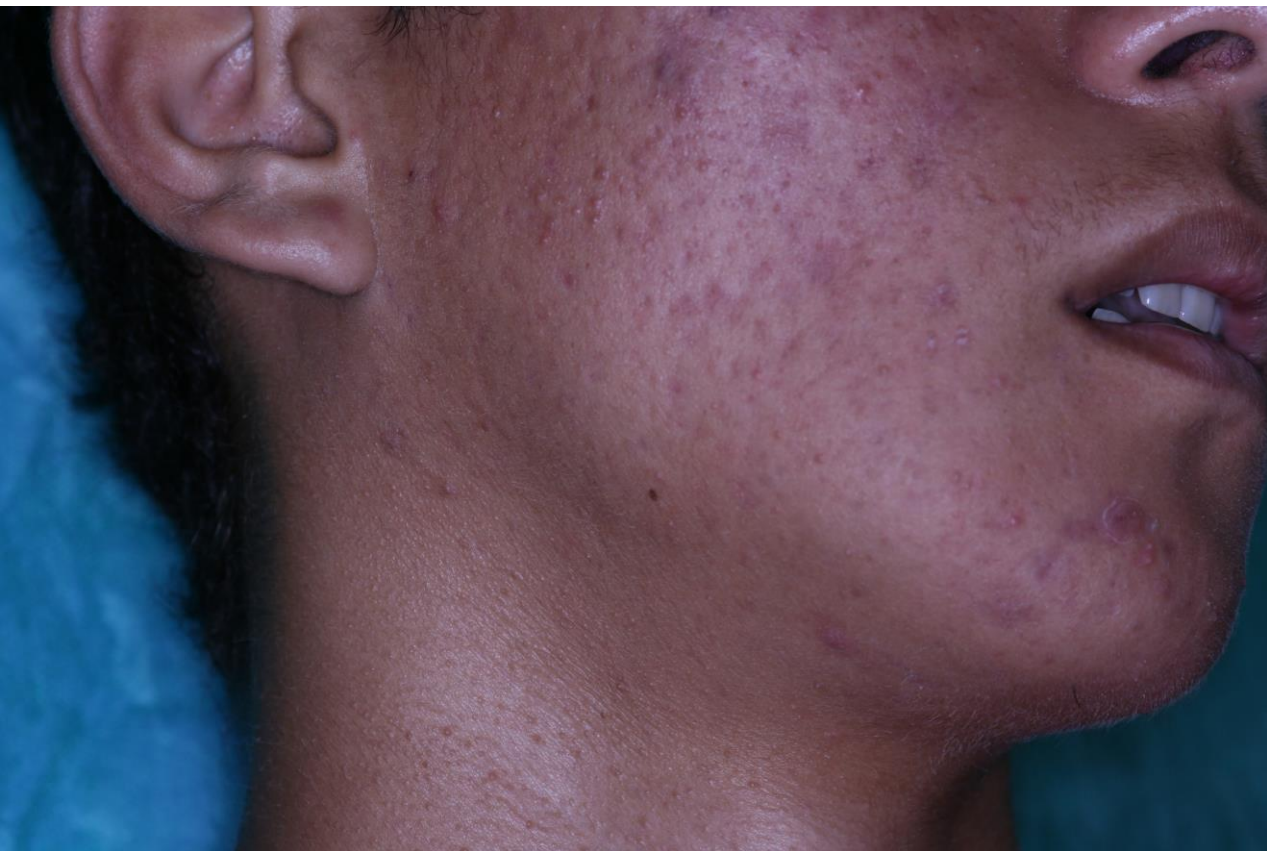
# Links para a lâmina:

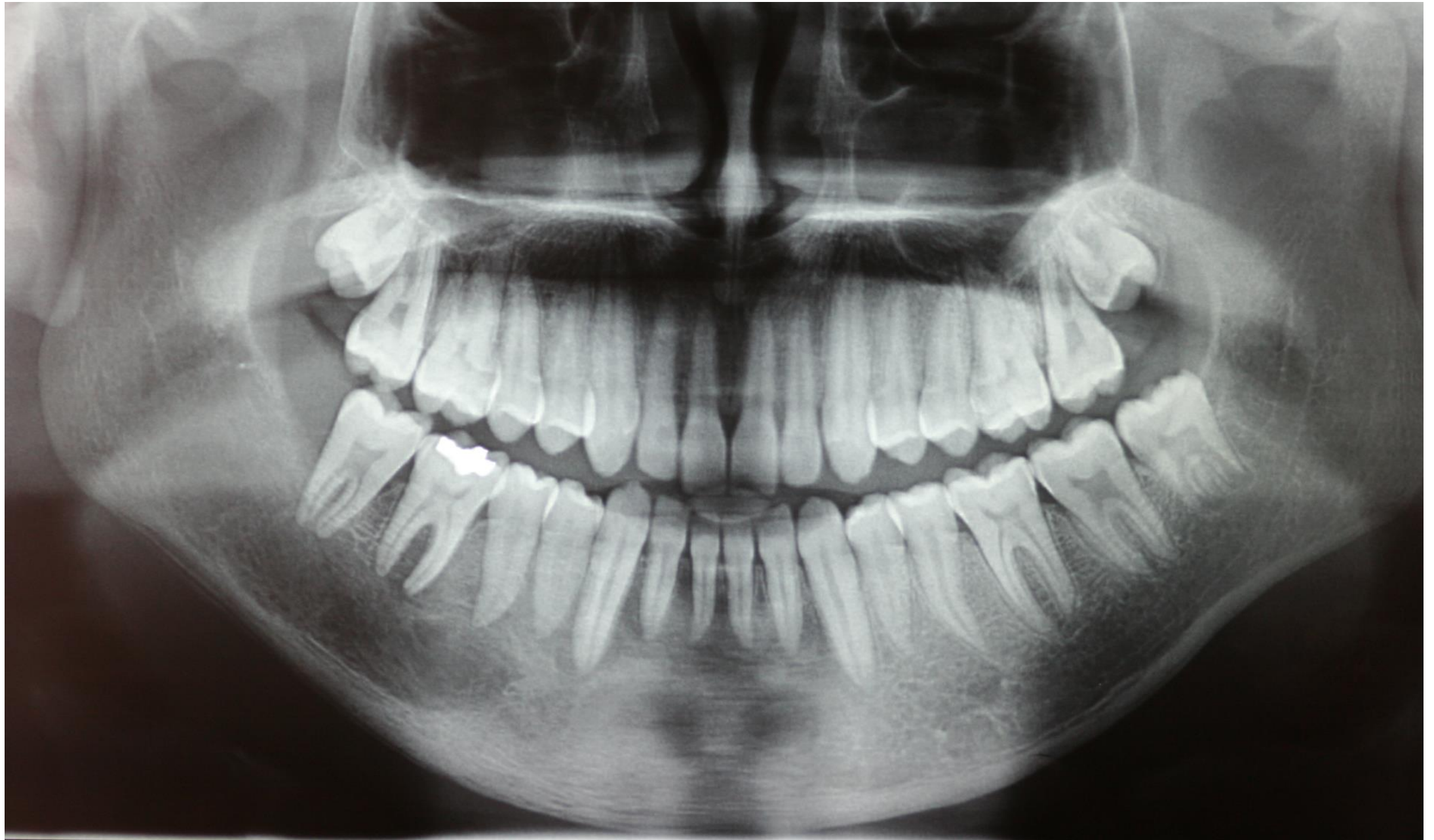- HE: <https://pathpresenter.net/public/display?token=b9631c12>

## CASO 2

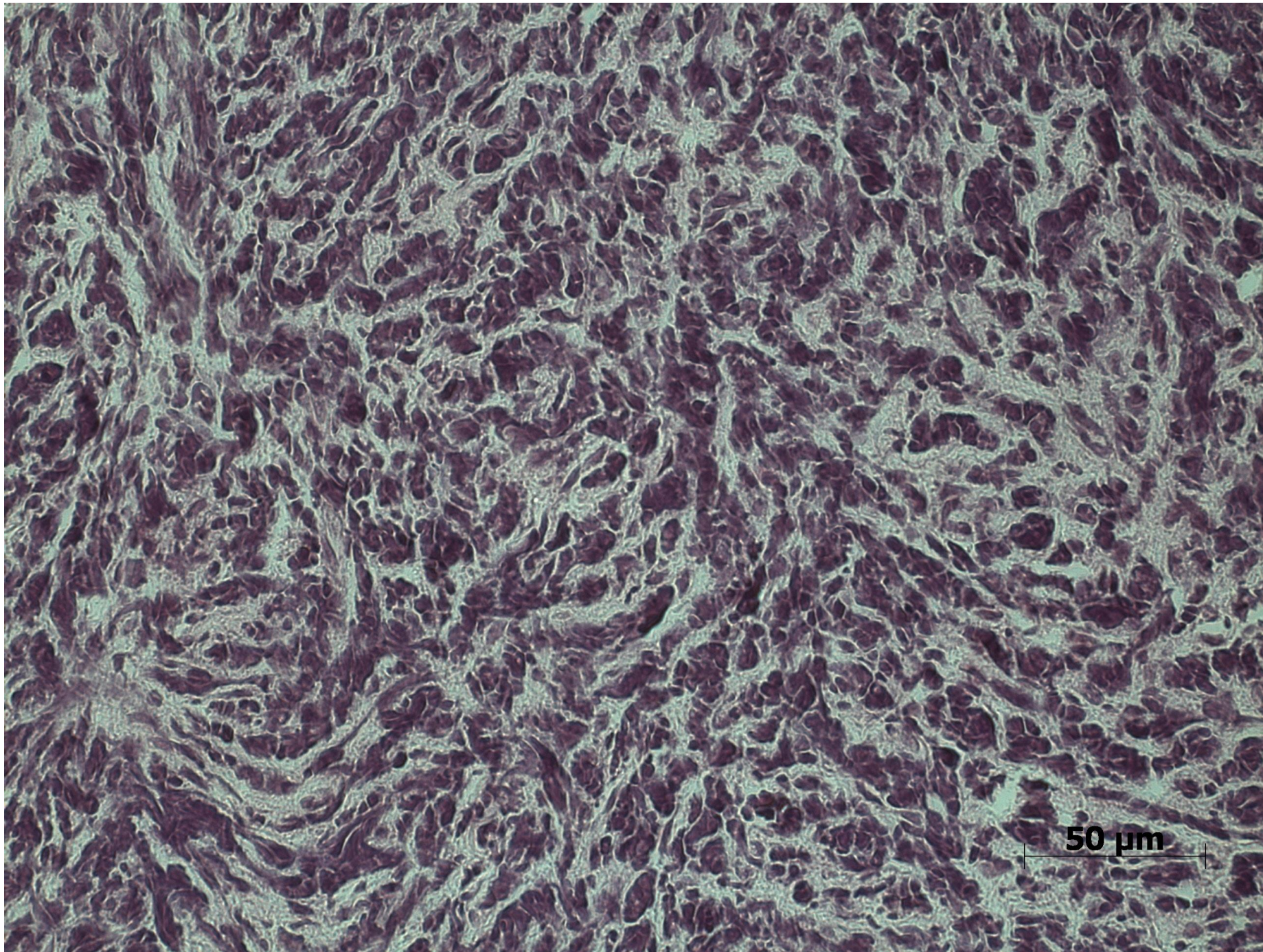
Paciente masculino, 17 anos. Encaminhado pela ortodontista.  
Desconhecia a presença de alterações em boca.



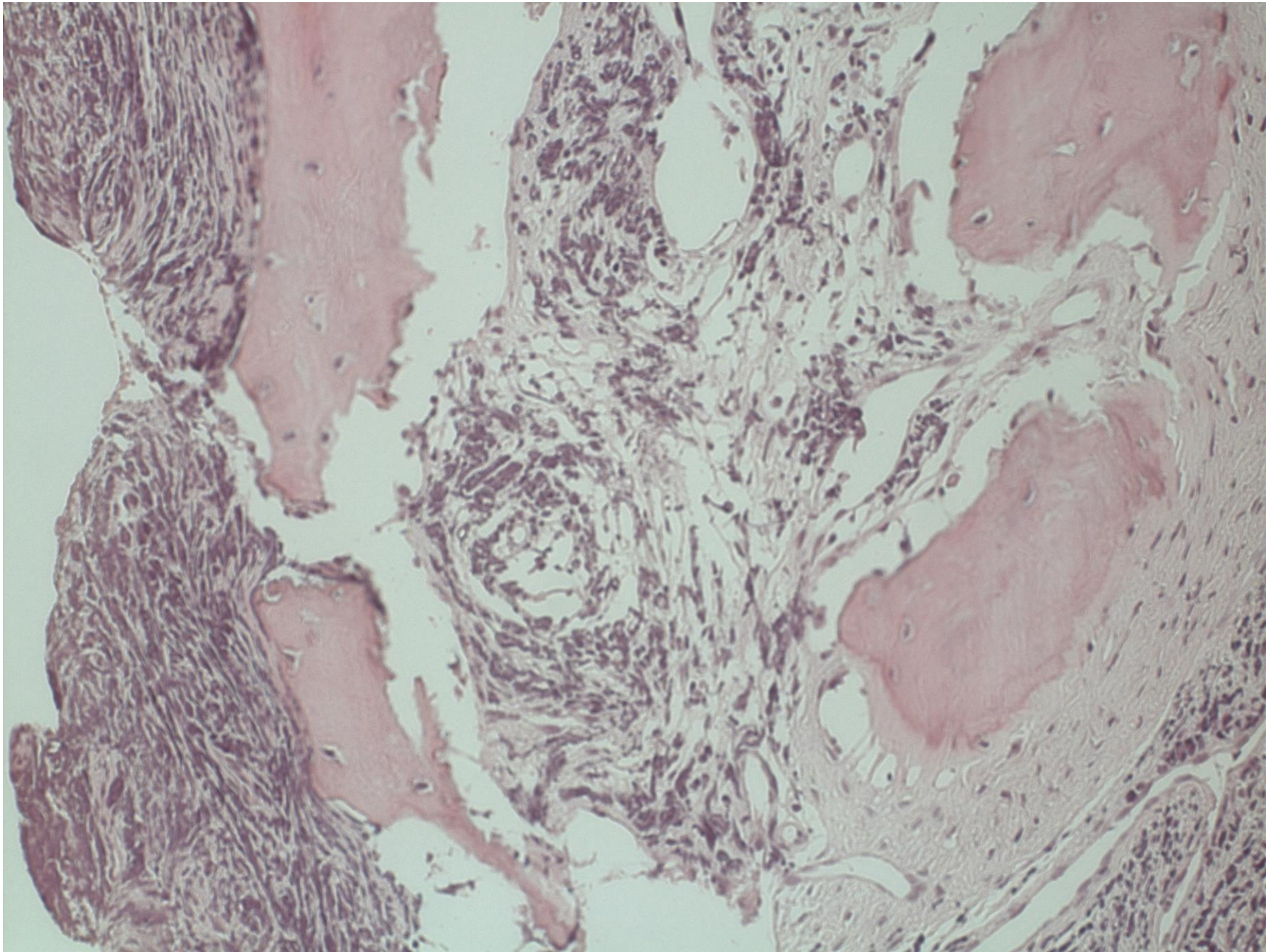




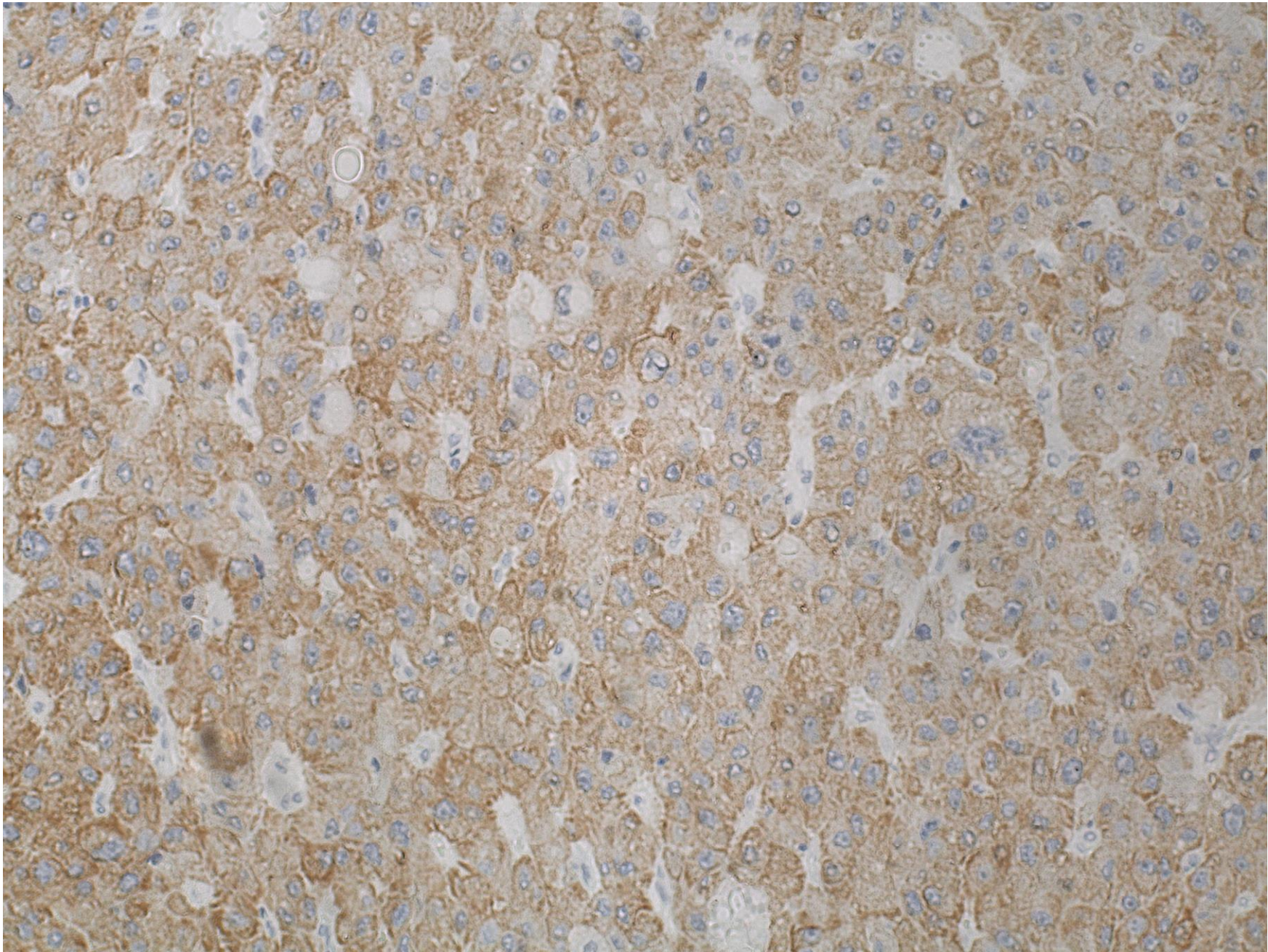












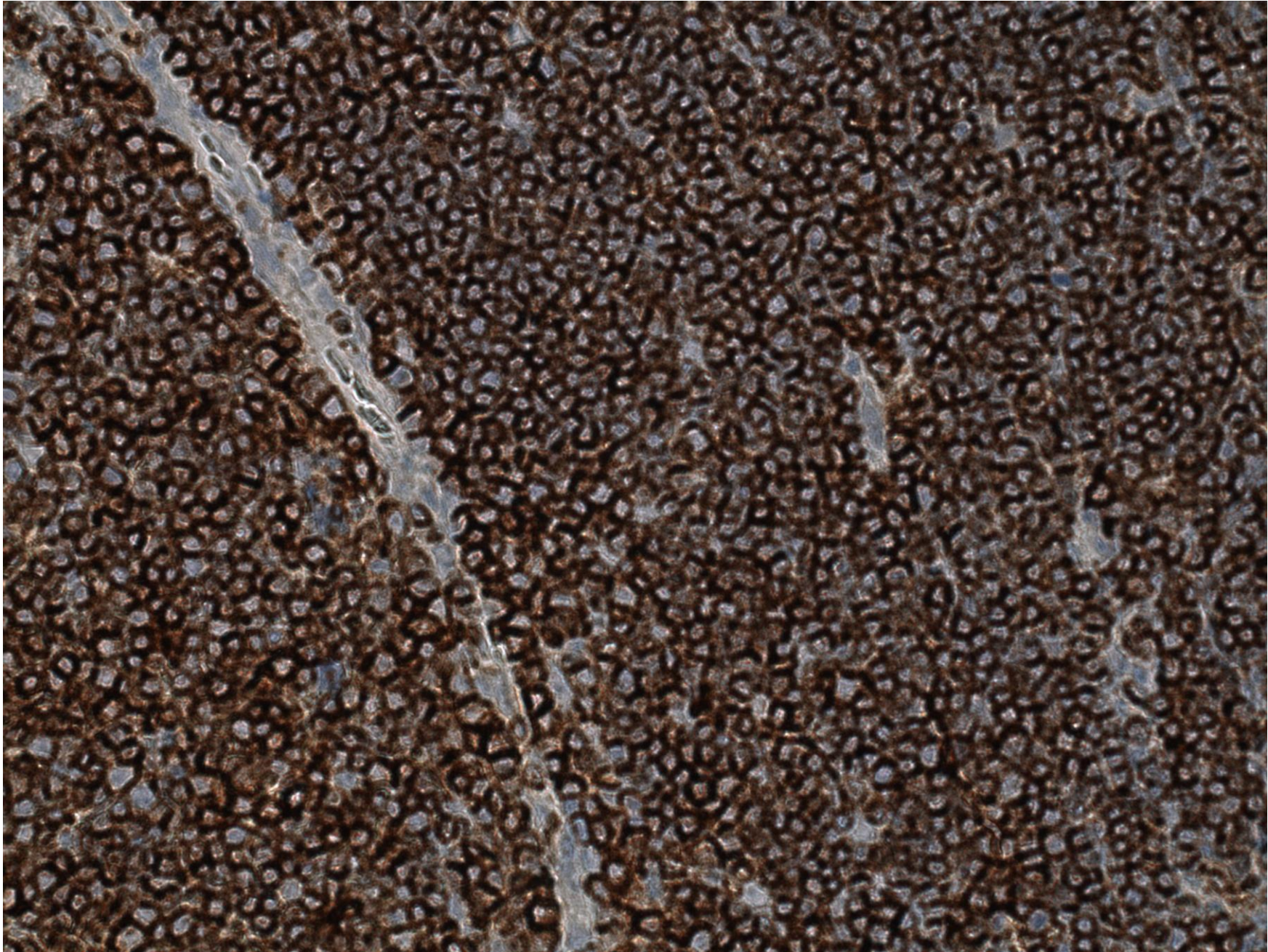
**AE1/AE3**





**CD45RO**



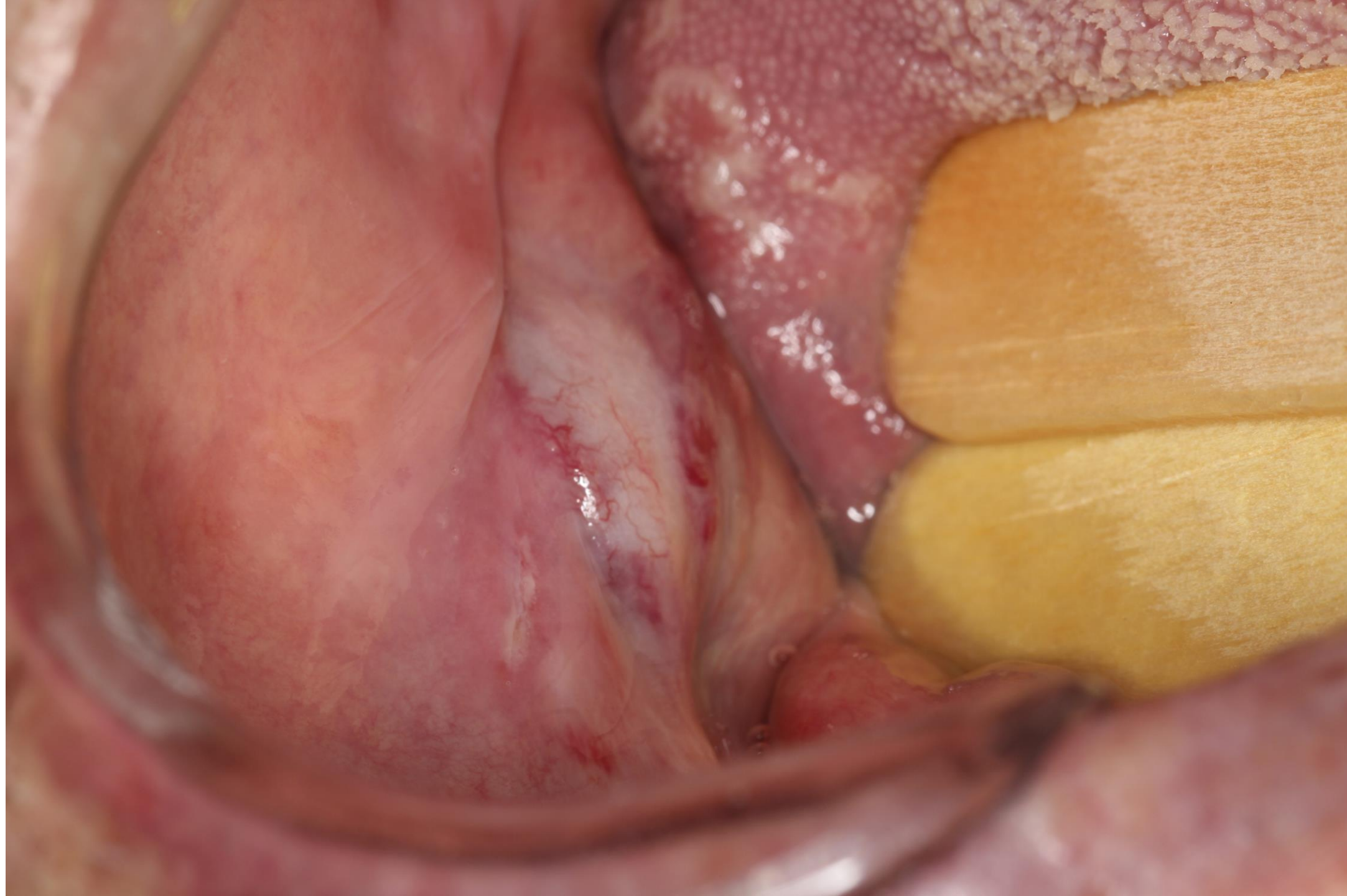


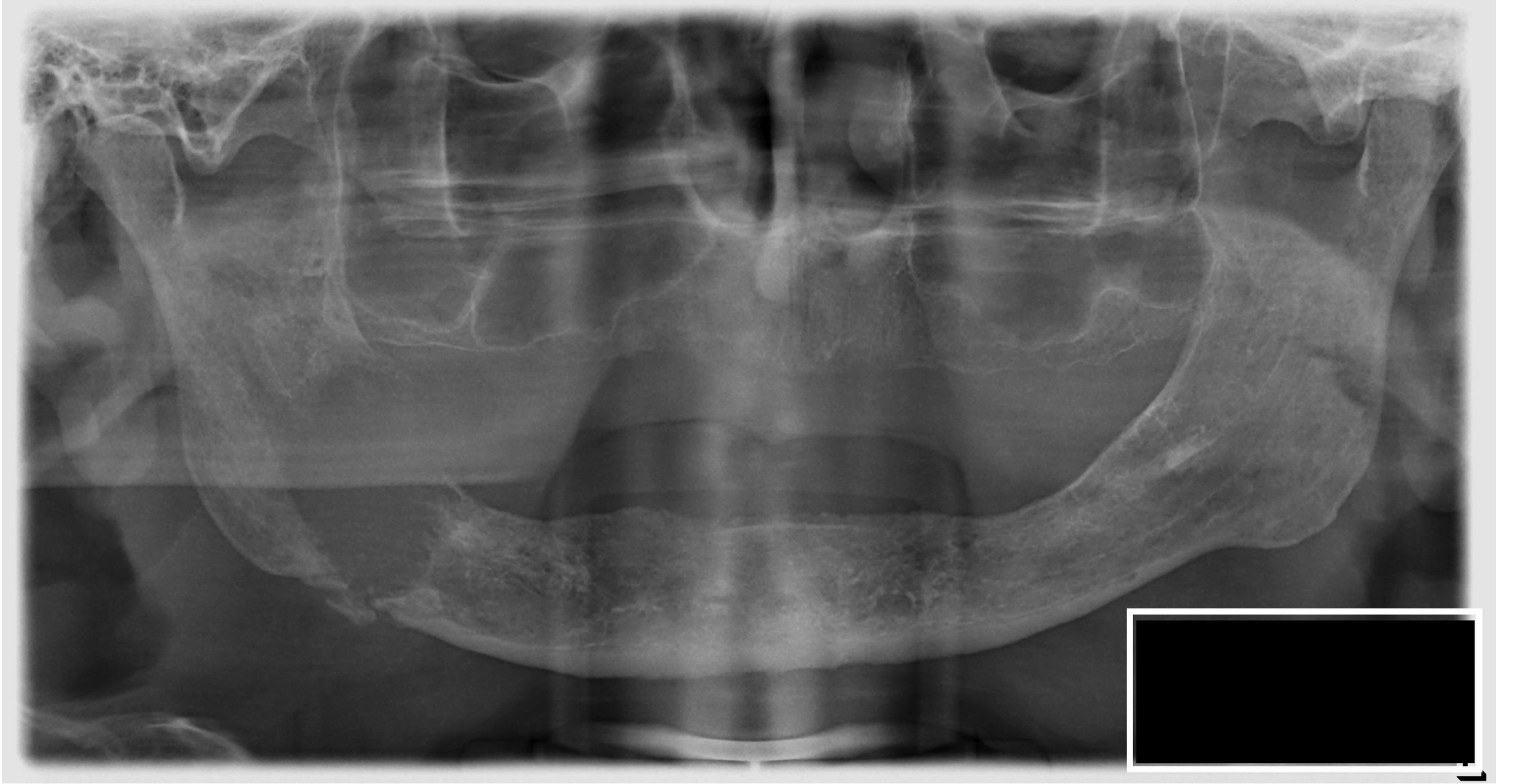
CD99

## CASO 3

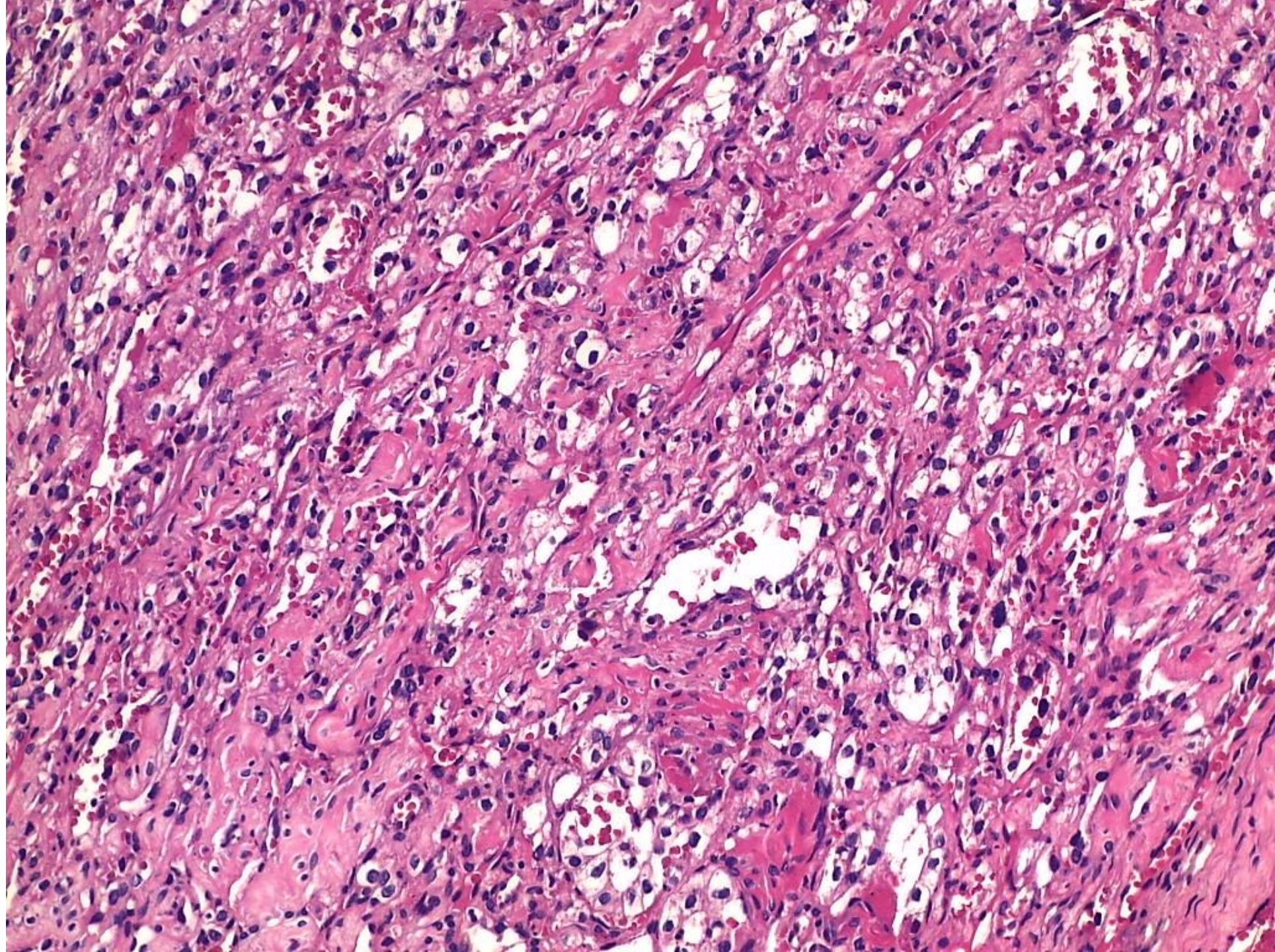
Paciente masculino, 89 anos. Queixa principal: “dor no osso”.



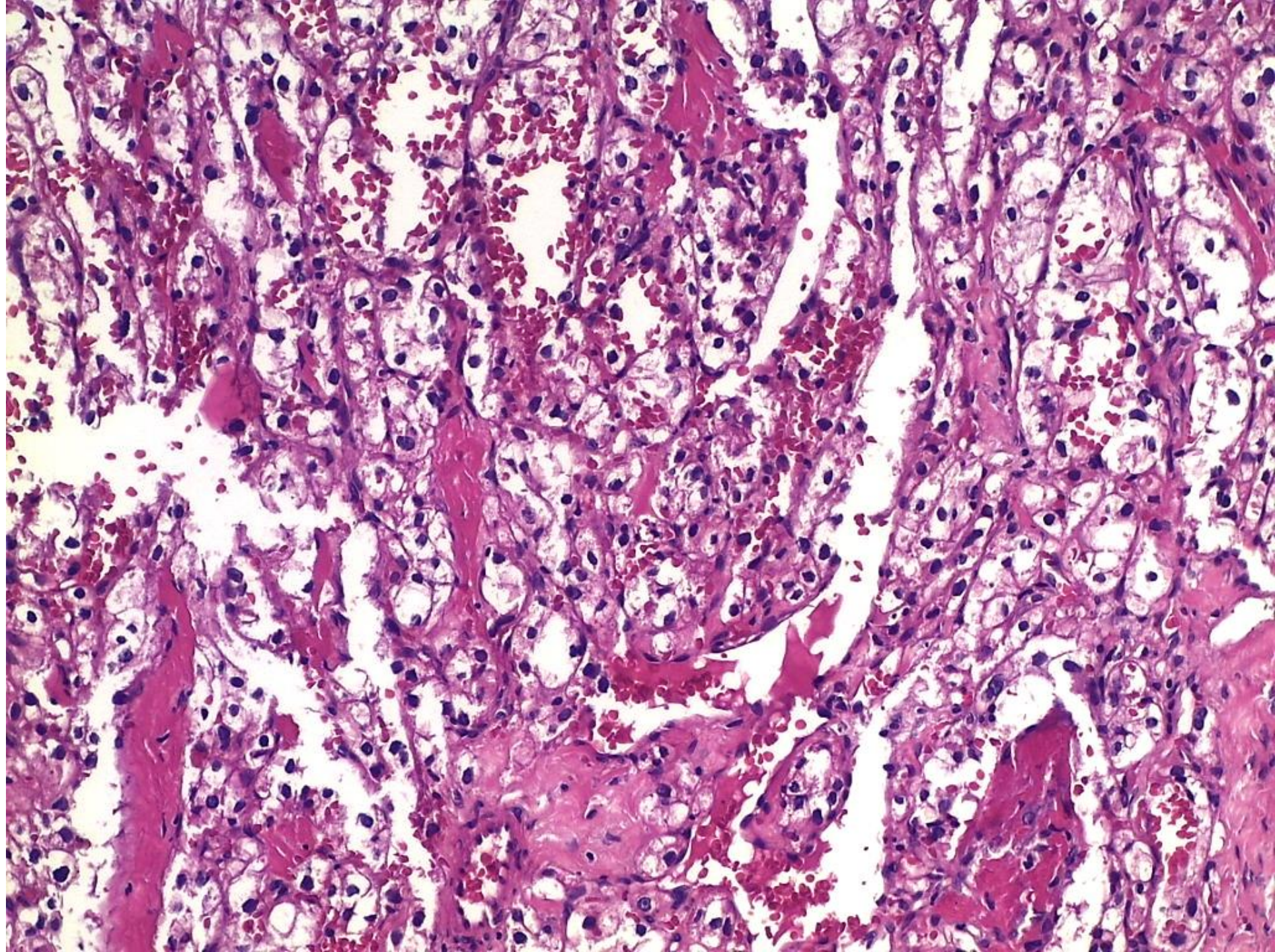




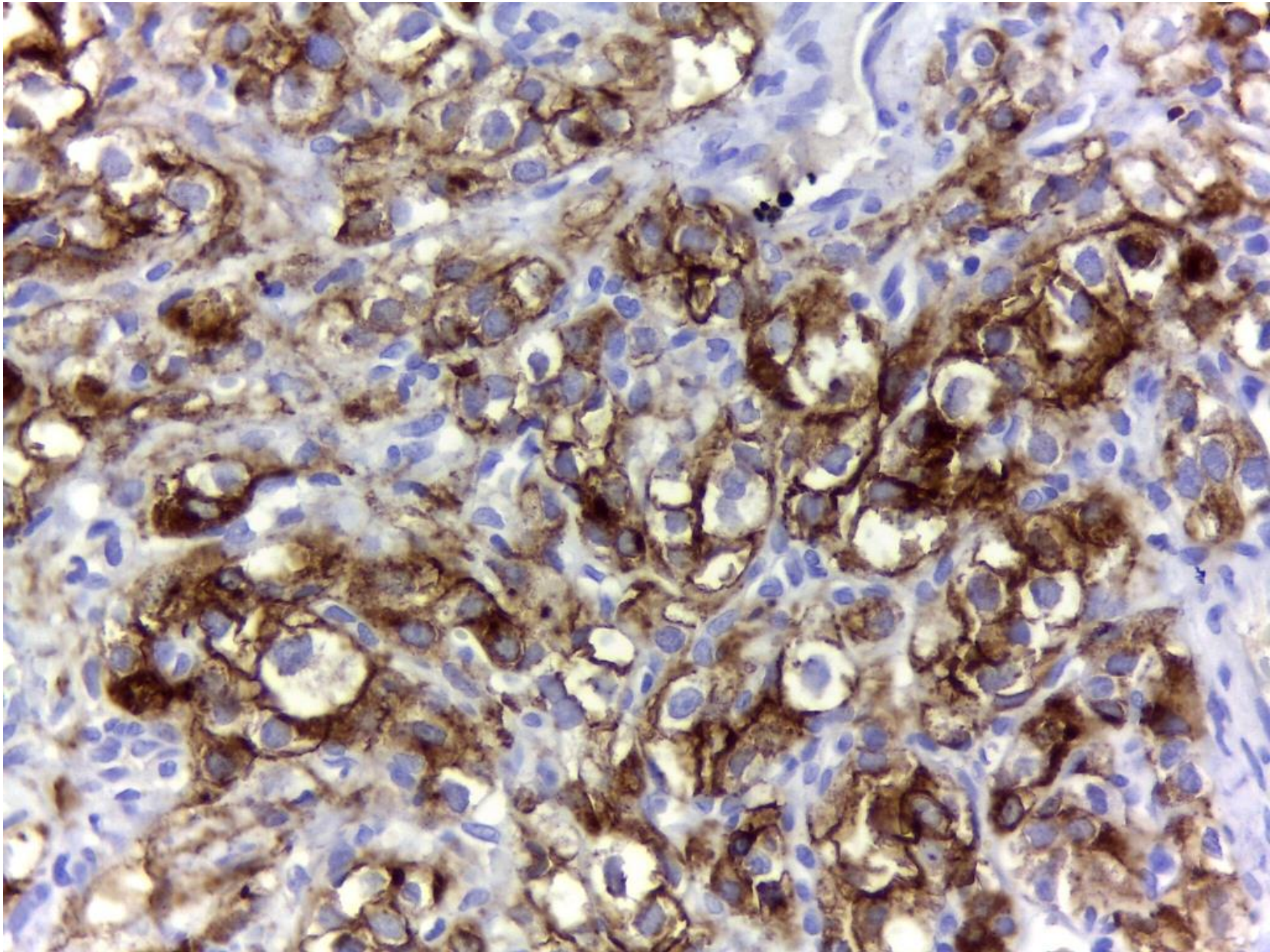






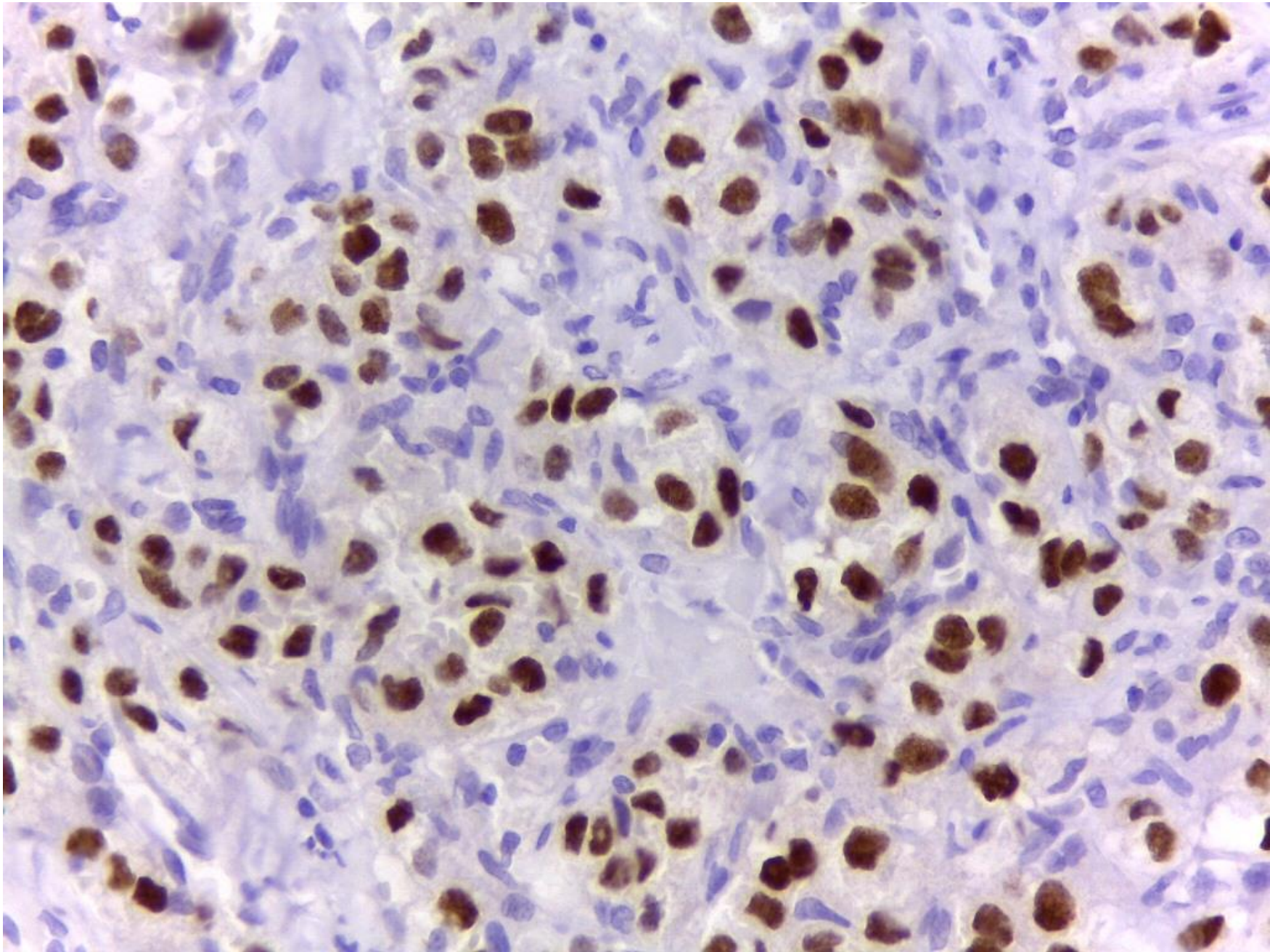






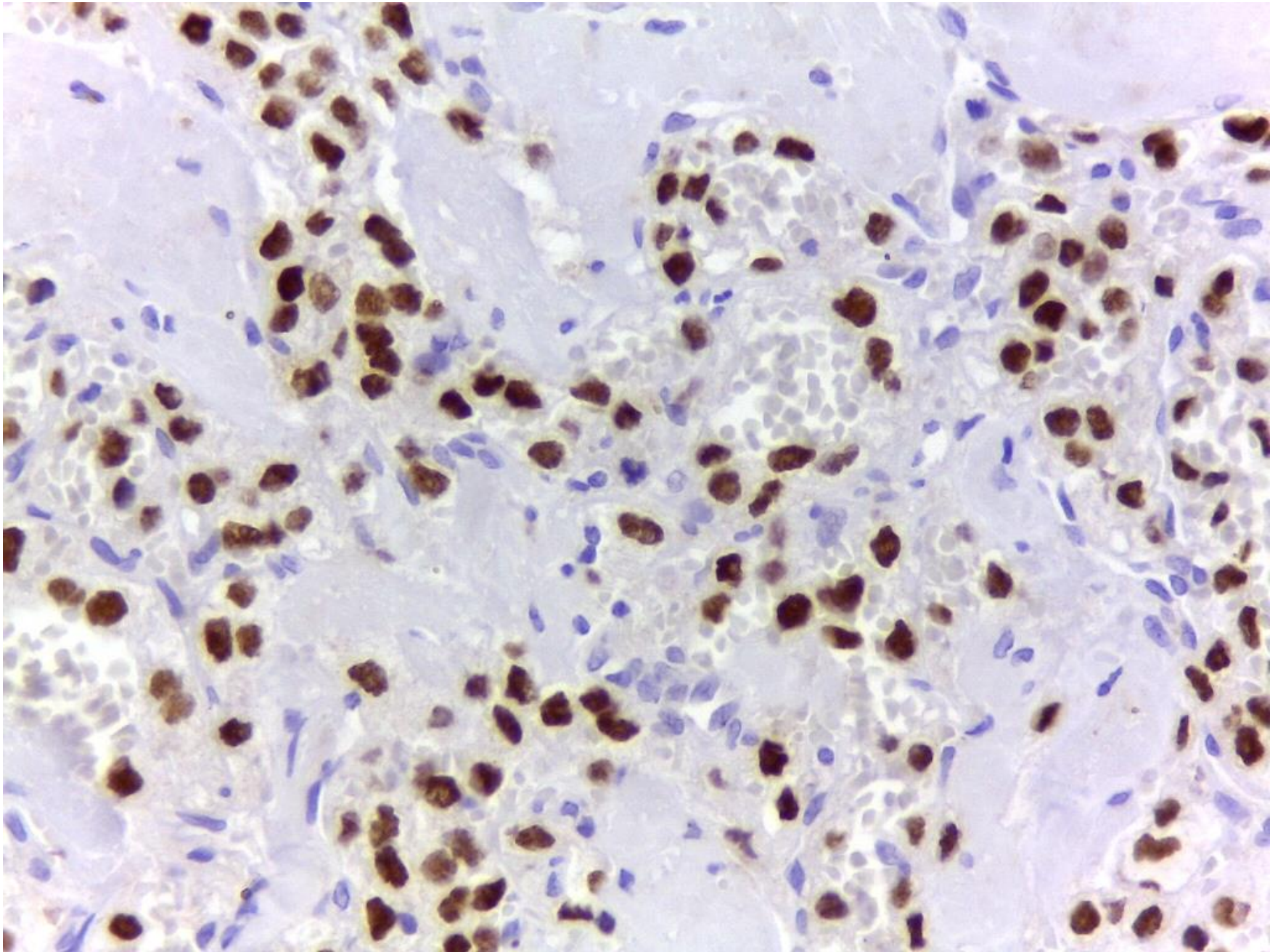
**CD10**





**PAX8**





**Ki67**